



5 Jinekoloji ve Obstetrikte Tartışmalı Konular Kongresi

5-8 Ekim 2023

Hilton Dalaman Sarıgerme



www.obstetrikjinekolojitartismalikonular.org

BİLİMSEL PROGRAM ve BİLDİRİ ÖZETLERİ KİTABI



5. Jinekoloji ve Obstetrikte Tartışmalı Konular Kongresi

5-8 Ekim 2023 | Hilton Dalaman Sarıgerme

İÇİNDEKİLER

ÖNSÖZ	3
KURULLAR.....	4-5
BİLİMSEL PROGRAM	6-14
SÖZLÜ BİLDİRİLER	15-68
VİDEO BİLDİRİLER	69-75
POSTER BİLDİRİLER	76-81



5. Jinekoloji ve Obstetrikte Tartışmalı Konular Kongresi

5-8 Ekim 2023 | Hilton Dalaman Sarıgerme

ÖNSÖZ

5. Jinekoloji ve Obstetrikte Tartışmalı Konular Kongresi, Kadın Sağlığı alanındaki en güncel tartışmalı konularla ilgilenen, konuşmacılarla katılımcıların birbiri ile etkileşimini yüz yüze görüşebilmesini önemseyen ve buna çok zaman ayrılmasını sağlayan, liyakata dayalı, kaliteyi ön planda tutan bir kongre olacaktır.

Kongremiz, dünya ve ülkemizin en seçkin bilim adamlarının katılımı, onların günlük pratiklerinde klinik ve tedavi konusunda deneyimleri ve karşılaştıkları sorunları etkin bir şekilde tartışma fırsatını sundukları bir ortam hazırlayacaktır.

5. Jinekoloji ve Obstetrikte Tartışmalı Konular Kongresi, Kadın Sağlığı alanında çalışan profesyoneller arasında; bilimsel, eğitsel ve sosyal alışveriş için en yüksek standartta bir forum sunmayı, araştırma ve eğitimi teşvik etme, yeni bilgiyi yayma şeklinde bir misyon üstlenmiştir.

5. Jinekoloji ve Obstetrikte Tartışmalı Konular Kongresine katılın ve şunları yapın:

Obstetrik ve Jinekolojide dünya ve ülkemizin liderleri ile tanışın. Benzersiz bir network platformunda, mesleğinizin diğer uzmanlarıyla görüşmeler sağlayın. Farklı bakış açıları ile diğer uzmanlık alanlarındaki profesyonellerle fikirleri paylaşın. Alanınızla ilgili konular hakkında daha fazla bilgi edinerek uygulamalarınızı zenginleştirin. Sadece 4 gün içinde Obstetrik ve Jinekolojide en yeni bilgilerle buluşun. Birçok konuda lider uzmanları sorgulama fırsatlarına sahip, etkileşimli oturumlara katılın. Diğer ülkelerden en iyi uygulamaları öğrenerek kendi pratiğinizi geliştirin. İlgi alanlarınıza odaklanmış oturumlara katılarak özel bilgilerle donanın. Alışılmışın dışında sunum teknikleri ve oturumları keşfedin. Fikir liderleriyle ilgilendiğiniz konuları birebir sorma şansını yakalayın. Jinekoloji ve Obstetrikte en son çalışmalarınızı poster sunumu veya oral sunumlarla bol bol paylaşın.

Bu toplantı Obstetrik ve Jinekolojide çığır açacak görüldüğü gibi birçok dernek ve fikir liderinin oluşturduğu birleştirici unsurları yüksek bir toplantı olacaktır. Tüm yan dallarla ilgili bilimsel kurullarımız ilgili derneklerimizin yönetimlerinin kararlarıyla oluşturulacaktır. Biz fikir liderleri sadece aracıyız. Tüm derneklerimizin yönetim ve üyeleri ise asıl gücümüz.

Bu derneklere ek katılmak isteyen her dernek veya alanımızdaki kuruluşa da kapımız daima açıktır.

Saygılarımızla,

Kongre Düzenleme Kurulu



5. Jinekoloji ve Obstetrikte Tartışmalı Konular Kongresi

5-8 Ekim 2023 | Hilton Dalaman Sarıgerme

JİNEKOLOJİ VE OBSTETRİK TARTIŞMALI KONULAR DERNEĞİ



Başkan

M. Faruk Köse

Başkan Yardımcısı

Mete Güngör

Genel Sekreter

Nejat Özgül

Sayman

M. Murat Naki

Üyeler

Ali Ayhan

Rıfat H. Gürsoy

M. Mutlu Meydanlı

U. Fırat Ortaç

Salih Taşkın



5. Jinekoloji ve Obstetrikte Tartışmalı Konular Kongresi

5-8 Ekim 2023 | Hilton Dalaman Sarıgerme

KONGRE DÜZENLEME KURULU

KONGRE BAŞKANI

Mete Güngör

KONGRE GENEL SEKRETERİ

M. Murat Naki

KONGRE BİLİMSEL KURULU

Ahmet Zeki Işık
Akın Sivaslıoğlu
Akın Usta
Ali Ayhan
Ali Haberal
Atıl Yüksel
Aytaç Yüksel
Baki Şentürk
Barış Ata
Burak Karadağ
Cem Batukan
Cem Demirel
Cihan İnanc
Cihan Uras
Cihat Ünlü
Coşkun Salman
Çetin Çelik
Davut Güven
Demir Özbaşar
Derman Başaran
Derya Kılıç
Doğan Vatansever
Ekin Fettahoğlu Ünlüer
Emine Karabük
Emre Mat
Erbil Doğan
Ercan Baştu
Erhan Şimşek
Esat Orhon
Esra Özbaşlı

Fatih Durmuşoğlu
Fırat Ortaç
Fuat Demirkıran
Gürkan Bozdağ
Gürkan Uncu
Hakan Seyisoğlu
Hüseyin Akıllı
Hüseyin Durukan
Hüseyin Gökemli
Hüsnü Çelik
Işıl Kasapoğlu
İbrahim Kalelioğlu
İbrahim Yalçın
İlkan Dunder
Kemal Güngördük
Kemal Özerkan
Kutay Biberoglu
Kübra Boynukalı
Levent Keskin
M. Ali Vardar
M. Faruk Köse
M. Murat Naki
Macit Arvas
Mete Güngör
Miğraci Tosun
Murat Gültekin
Mutlu Meydanlı
Müfit Yenen
Nasuh Utku Doğan
Nejat Özgöl

Nuri Danışman
Oğuzhan Kuru
Oluş Api
Ozan Doğan
Özgüç Takmaz
Özgür Deren
Özlem Pata
Pınar Yalçın Bahat
Recep Has
Rıza Madazlı
Rifat Gürsoy
Salih Taşkın
Samet Topuz
Seda Şahin Aker
Serdar Özşener
Sezcan Mümmüşoğlu
Suat Dede
Süleyman Salman
Şevki Çelen
Tamer Mungan
Turgut Aydın
Tülin Dabakoğlu
Umut Dilek
Yakup Kumtepe
Yaprak Üstün
Yavuz Emre Şükür
Yılmaz Güzel
Yusuf Üstün

BİLİMSEL PROGRAM



www.obstetrikjinekolojiktartismalikonular.org



5. Jinekoloji ve Obstetrikte Tartışmalı Konular Kongresi

5-8 Ekim 2023 | Hilton Dalaman Sarıgerme

5 Ekim 2023, Perşembe

SALON 1

13:00-14:00

Prenatal Tanı ve Bakım

Moderatör: Atıl Yüksel

Panelistler: Recep Has, İbrahim Kalelioğlu, Aytaç Yüksel

- Noninvaziv Prenatal Tarama
- cF-DNA Tarama-Tanı? Etik? Avantaj ve Limitasyonlar
- Erken Doğum Tehditinde Serklaj- Progesteron
- LMAH ve/veya Aspirin Kullanımı
- Obstetride Magnezyum Kullanımı
- Antenatal Kortikosteroid Kullanımı

14:00-15:00

Anormal Uterin Kanamalar

Moderatör: Hüsnü Çelik

Panelistler: Ali Haberal, Samet Topuz, Çetin Çelik

- Sınıflandırma (PALM-COEIN)
- Endometrial Polip-Myom
- Endometrial Hiperplazi (EIN)

15:00-15:30

KAHVE ARASI

15:30-16:30

İntrapartum Bakım

Moderatör: Recep Has

Panelistler: Özlem Pata, Özgür Deren, Umut Dilek

- Doğum İndüksiyonu
- Epizyotomi
- Operatif Doğum (Vakum, Forseps, Sezaryen)
- Travayın Uzaması
- Travayda Kardiyotokograf Kullanımı
- İntrapartum Hipoksi

16:30-17:30

Endometriozis ve İnfertilite

Moderatör: Gürkan Uncu

Panelistler: Ercan Baştu, Işıl Kasapoğlu, Yavuz Emre Şükür

- Endometriozis ve Oosit Kalitesi Üzerine Etkisi
- Oosit Kriyoprezervasyonunun Yeri
- Cerrahi vs İVF?
- Endometrioma- Direkt Cerrahi vs İVF Sonrası Cerrahi
- Endometrioziste Fertilitenin Korunması

17:30-17:45

Açılış Konuşması

Mete Güngör



5. Jinekoloji ve Obstetrikte Tartışmalı Konular Kongresi

5-8 Ekim 2023 | Hilton Dalaman Sarıgerme

6 Ekim 2023, Cuma

SALON 1

08:30-09:30

PKOS

Moderatör: Gürkan Bozdağ

Panelistler: Yaprak Üstün, Sezcan Mümüşoğlu, Kübra Boynukalın

- Tanımlar (PKO/PKOS)'a Yeni Bakış
- Tanı
- Metabolik Sendrom
- Adölesanda PKOS
- Fertiliteye Etkisi
- PKOS ve Endometrium
- Perimenopozda PKOS
- Tedavi (OK, Miyo-Inositol vs)

09:30-10:00

UYDU SEMPOZYUMU

Gebelikte Yeni Akım: Tdap Aşılması

Moderatör: M. Murat Naki

Konuşmacı: Özlem Pata

sanofi

10:00-10:30

KAHVE ARASI

10:30-11:30

Her Yönüyle Laparoskopik ve Robotik Histerektomi

Moderatör: İlkan Dünder

Panelistler: Kemal Özerkan, Salih Taşkın, Levent Keskin, Doğan Vatansever

- Trokar Sayıları ve Yeri
- Manipülatör Kullanımı
- Üreter Disseksiyonu
- Kolpotomi Tekniği
- Vagen Kafının Kapatılması
- Zor Histerektomideki Püf Noktaları
- ERAS Protokolleri ve Postop LMAH Kullanımı

11:30-12:15

UYDU SEMPOZYUMU

HPV, ilişkili Hastalıklar ve Kanseler,

HPV Aşılarında Güncel Durum

Konuşmacı: M. Faruk Köse

MSD

12:15-13:00

ÖĞLE YEMEĞİ



5. Jinekoloji ve Obstetrikte Tartışmalı Konular Kongresi

5-8 Ekim 2023 | Hilton Dalaman Sarıgerme

6 Ekim 2023, Cuma

SALON 1

13:00-14:00 **Servikal Preinvaziv Lezyonlar Tarama ve Takibi**
Moderatör: Fırat Ortaç
Panelistler: Fuat Demirkıran, Müfit Yenen, Nejat Özgül, Coşkun Salman
- Servikal Kanser Taramasında Güncel Durum
- ASCCP Yeni Sitolojik Yönetim
- ASCCP Yeni Histolojik Yönetim
- Kolposkopi
- Eksizyonel Tedaviler

14:00-15:00 **Myomlarda Laparoskopik ve Robotik Cerrahi**
Moderatör: M. Murat Naki
Panelistler: Cem Demirel, Suat Dede, Özgüç Takmaz
- Trokar Yerleşimi ve Sayıları
- Myomektomi Tekniği
- Vazokonstrüktör Kullanımı, ERAS protokolleri, Preop ve Postop Antikoagulan Kullanımı
- Sütürasyon Tekniği
- Morselasyon Yöntemleri

15:00-15:15 KAHVE ARASI

15:15-15:45 **UYDU SEMPOZYUMU**
HPV Pozitif Hastalarda Tedavi Gerekli mi?
Bekle-Gör vs. Non-Invasive Tedaviler
Konuşmacı: Murat Gültekin



15:45-16:45 **Kontrasepsiyon**
Moderatör: Cihat Ünlü
Panelistler: Kutay Biberoğlu, Erbil Doğan, Emine Karabük
- Oral Kontrasepsiyonda Yenilikler
- Rahim İçi Sistemler
- Cilt Altı Kontrasepsiyon Yöntemleri
- Vaginal Ringler



5. Jinekoloji ve Obstetrikte Tartışmalı Konular Kongresi

5-8 Ekim 2023 | Hilton Dalaman Sarıgerme

6 Ekim 2023, Cuma

SALON 1

16:45-17:45

Gebelik ve Hipertansiyon - IUGR

Moderatör: *Özgür Deren*

Panelistler: *Rıza Madazlı, Miğraci Tosun, Şevki Çelen*

- Erken ve Geç Başlangıçlı Gelişme Geriliklerinin Güncel Yönetimi
- Yeni Ne Var?
- Doğum Bir Çözüm mü?
- Komplikasyonların Önlenmesi
- Kronik Hipertansiyon
- Gebelik Hipertansiyonu Tanımı, Etiopatogenezi ve Önlenmesi
- Erken ve Geç Başlangıçlı Preeklampsinin Güncel Yönetimi
- Medikal Tedavi
- HELLP Sendromu
- Kronik Hipertansif Olgularda Gebelik Yönetimi
- İntrapartum ve Postpartum Yönetimi

6 Ekim 2023, Cuma

SALON 2

10:00-11:30

Video Sunumlar (VS-01 / VS-13)

Moderatör: *Emine Karabük, Hüseyin Akıllı*

13:00-14:30

Sözel Sunumlar - 1 (SS-01 / SS-15)

Moderatör: *Demir Özbaşar, Ozan Doğan*

16:00-17:30

Sözel Sunumlar - 2 (SS-16 / SS-30)

Moderatör: *Aytaç Yüksel, Kemal Güngördük*



5. Jinekoloji ve Obstetrikte Tartışmalı Konular Kongresi

5-8 Ekim 2023 | Hilton Dalaman Sarıgerme

7 Ekim 2023, Cumartesi

SALON 1

08:30-09:30 **Gebelikte Ultrason (Prekonsepsiyonel, Perinatal, İntrapartum, Postpartum)**
Moderatör: Nuri Danışman
Panelistler: Oluş Api, Cem Batukan, Cihan İnan
- 1. Trimester
- 2. Trimester
- 3. Trimester
- Doğumda Ultrason
- Postpartum Ultrason

09:30-10:30 **Olgularla Adneksiyel Kitlelere Yaklaşım**
Moderatör: Ali Ayhan
Panelistler: Macit Arvas, M. Mutlu Meydanlı, Baki Şentürk, İbrahim Yalçın
- Adneksiyel Kitlelerin Değerlendirilmesi
- Şüpheli Adneksiyel Kitlelere Yaklaşım
- L/S vs Laparotomi
- Gebelikte Adneksiyel Kitleler
- Menopozda Adneksiyel Kitleler

10:30-11:00 **KAHVE ARASI**

11:00-11:30 **UYDU SEMPOZYUMU**
Kadın Kastalıkları ve Doğumda Koenzim q10 ve Omega3 Kullanımı
Konuşmacı: M. Murat Naki



11:30-12:30 **Ovulasyon İndüksiyonu - IUI - IVF**
Moderatör: Barış Ata
Panelistler: Gürkan Bozdağ, Turgut Aydın, Burak Karadağ
- Anovulasyonun En Rasyonel Tanısı Hangisidir?
- Oral Preparatların Yeri Hala Var mı? Kime Ne Zaman, Klomifen mi Aromataz İnhibitörleri mi? Etki, Yan Etki ve Riskler Açısından Farklar Var mı?
- Klomifen + Glukokortikoid veya Klomifen + Metformin Gereken Durumlar Hangileridir? Fark Yaratır mı?
- Klomifen ve Aromataz İnhibitörleri Sikluslarında Hcg Tetiklemesi Gerekli midir?
- Gonadotropin Tedavisi; Ne Zaman, Hangi Hastaya, Hangi Gonadotropin, Hangi Protokol?
- Ovulasyon İndüksiyonunda Monitorizasyon; Ultrasonografi mi, Serum Estradiol mü, Oral Preparatlarda da Gerekli mi?
- OHSS ve Çoğul Gebeliklerden Kaçınma Stratejileri Nelerdir?
- Ovulasyon İndüksiyonu Over ve Meme Kanseri Riskini Artırır mı?

12:30-13:15 **ÖĞLE YEMEĞİ**




5. Jinekoloji ve Obstetrikte Tartışmalı Konular Kongresi

5-8 Ekim 2023 | Hilton Dalaman Sarıgerme

7 Ekim 2023, Cumartesi

SALON 1

13:15-13:45	UYDU SEMPOZYUMU Kadın Gücü: Magnezyumla Hayat Boyu Destek Moderatör: <i>M. Murat Naki</i> Konuşmacı: <i>Feyza Özdemir</i>	
13:45-14:45	Fonksiyonel Tıp Oturumu Moderatör: <i>Yaprak Üstün</i> Panelistler: <i>Tülin Dabakoğlu, Pınar Yalçın Bahat, Ekin Fettahoğlu Ünlüer</i> <ul style="list-style-type: none">- PKOS- Östrojen Dominansı- Klimakterium- PMS / PMDD- Gebelik Dönemi- Vaginal Enfeksiyonlar	
14:45-15:45	Postpartum Kanama Moderatör: <i>Samet Topuz</i> Panelistler: <i>Nuri Danışman, Tamer Mungan, Oğuzhan Kuru, Hüseyin Durukan</i> <ul style="list-style-type: none">- Tanım, Etiyopatogenez, İnsidans ve Risk Faktörleri- Medikal Tedavi Yaklaşımı- Cerrahi Tedavi Yaklaşımı- Traneksamik Asid Kullanımı- Embolizasyon	
15:45-16:15	KAHVE ARASI	
16:15-17:15	Her Yönüyle Histeroskopi Moderatör: <i>Ahmet Zeki Işık</i> Panelistler: <i>Erhan Şimşek, Yılmaz Güzel, Nasuh Utku Doğan, Derman Başaran</i> <ul style="list-style-type: none">- Histeroskopi Tekniği - Enstrümanlar- Tanısal Histeroskopi- İnfertil Olgularda Histeroskopi- Onkolojide Histeroskopi	
17:15-18:15	Vajinit: Genel Bakış Moderatör: <i>Yusuf Üstün</i> Panelistler: <i>Akın Usta, Emre Mat, Esra Özbaşı</i> <ul style="list-style-type: none">- Vajinit Tanı ve Tedavisi- Etiyoloji, Risk Faktörleri, Semptomlar- Vaginal Mikrobiyom- İnflamatuvar/Atrofik Vajinit- Kronik Vajinitlere Yaklaşım- Rekürren Vulvovajinitler	



5. Jinekoloji ve Obstetrikte Tartışmalı Konular Kongresi

5-8 Ekim 2023 | Hilton Dalaman Sarıgerme

7 Ekim 2023, Cumartesi

SALON 2

11:30-13:00 **Sözel Sunumlar - 3 (SS-31 / SS-45)**
Moderatör: *M. Murat Naki, Seda Şahin Aker*

13:00-14:00 **ÖĞLE YEMEĞİ**

14:00-15:30 **Sözel Sunumlar - 4 (SS-46 / SS-59)**
Moderatör: *Erhan Şimşek, Hüseyin Akıllı*

15:30-17:00 **Sözel Sunumlar - 5 (SS-60 / SS-73)**
Moderatör: *Derman Başaran, Özgüç Takmaz*



5. Jinekoloji ve Obstetrikte Tartışmalı Konular Kongresi

5-8 Ekim 2023 | Hilton Dalaman Sarıgerme

8 Ekim 2023, Pazar

SALON 1

09:00-10:00

Menopoz

Moderatör: Hakan Seyisoğlu

Panelistler: Cihan Uras, Fatih Durmuşoğlu, Serdar Özşener

- Menopozda Genel Sağlık
- Menopozal Yakınmaların Klinik Önemi ve Yönetimi
- Menopozal Hormon Tedavisinde Prensipler
- Postmenopozal Osteoporoz ve Tedavide Yenilikler
- MHT ve Meme
- Menopozda Yeni Tedavi Modaliteleri

10:00-11:00

Progesteron

Moderatör: Rifat Gürsoy

Panelistler: Esat Orhon, M. Ali Vardar, Davut Güven, Hüseyin Görkemli

- İnfertilitede Kullanımı
- Gebelikte Kullanımı
- Jinekolojide Kullanımı
- Onkolojide Kullanımı

11:00-11:30

KAHVE ARASI

11:30-12:30

Her Yönüyle İnkontinans

Moderatör: Yakup Kumtepe

Panelistler: Akın Sivaslıoğlu, Yusuf Üstün, Süleyman Salman, Derya Kılıç

- Antiinkontinans: Kime, Hangi Cerrahi?
- Askı Cerrahisi Komplikasyonları ve Yönetimi
- L/S Sakrokolpopeksi, Lateral Süspansiyon, Pektopeksi
- Posterior İntravaginal Slingoplasty (PIVS), Sakrospinöz Fiksasyon, İliokoksigeal Fiksasyon
- Sistosel Tanısı Nasıl Konulmalıdır?
- Rektosel Tanısı Nasıl Konulmalıdır? Etkin Tedavi Nedir?
- Vaginal Histerektomide İp Uçları Nelerdir?

12:30

KAPANIŞ

SÖZLÜ BİLDİRİLER



www.obstetrikjinekolojitarismalikonular.org



5. Jinekoloji ve Obstetrikte Tartışmalı Konular Kongresi

5-8 Ekim 2023 | Hilton Dalaman Sarıgerme

SS-03

Which management is more effective in triplet pregnancies after spontaneous delivery of one fetus: Conservative management or cerclage placement?

Sezin Ozyurt¹, Halil Korkut Dağlar²

¹Private Clinic, Mersin, Turkey

²Private Clinic, Mersin, Turkey

OBJECTIVE: The purpose of this two cases series' was to determine which management could prolong the pregnancy in triplet pregnancies after cervical dilatation. Does prophylactic cerclage plus antibiotherapy improves pregnancy outcome or expectant management with antibiotherapy prolong the pregnancy ?

METHOD: Two cases of triplet pregnancy with conservative management and cerclage placement after spontaneous delivery of one foetus, are presented and compared with cases in the literature. Both cases were trizygotic triamniotic IVF (in vitro fertilization) triplet pregnancies and both cases refused fetoscopy procedure.

Two different ways of treatment after cervical dilatation and literature suggestions were told to the families so they could be included into the process. First case was treated with cerclage placement after spontaneous dilatation of cervix and delivery of the prominent fetus. Second case decided to be treated conservatively. In spite of they choose different ways of treatment, tocolytic agents and antibiotic therapy were the same. In this manner, the role of tocolysis, cerclage, prophylactic antibiotic therapy and corticosteroids are discussed. **RESULTS:** After abortion of the prominent fetus, contractions often persist and the birth of the two remaining fetuses may be inevitable. Despite of the treatment with tocolytic agents and triple antibiotherapy, first case was aborted at the 24 weeks of pregnancy after early membrane rupture and excessive bleeding. The babies lived only 12 hours, died because of immaturity. An emergency cesarean section was performed for the second case at the 26 +3 weeks of pregnancy due to preterm labor. After 3 months intensive care unit follow up, the babies of the second case had survived. No maternal complications with sequelae are reported. **CONCLUSION:** Prophylactic cerclage did not result in improved pregnancy or neonatal outcomes in triplet pregnancies after cervical dilatation and spontaneous delivery of the prominent fetus. According to the limited literature findings we need more data to evaluate the management of treatment of preterm delivery in triplet pregnancies.

Keywords: cerclage, multiple gestation, triplets, premature,

SS-04

Paracervical Block Before Laparoscopic Total Hysterectomy: A Randomized Controlled Trial

Kemal Gungorduk, Berican Şahin Uyar, Leyla Taştan
Division of Gynecologic Oncology, Department of Obstetrics and Gynecology, Faculty of Medicine, Muğla Sıtkı Kocman University, Mugla, Turkey

OBJECTIVE: To test the hypothesis that paracervical bloc with 5 % bupivacaine would decrease postoperative pain after total laparoscopic hysterectomy (TLH).

METHODS: This randomized double-blind place control trial included 152 women. Ten milliliters of 5% bupivacaine with epinephrine (study group, n = 75) or 10 mL of normal saline (control group, n= 77) was infiltrated at the 3 and 9 o'clock position of the uterine cervix. The primary outcome was a visual analog scale score (VAS) for 1 hour postoperatively.

RESULTS: There were no differences in baseline demographics or perioperative characteristics. The mean VAS on postoperative 1 hour was significantly lower in the study group compared with the control group (5.9 ± 1.4 vs 6.8 ± 1.1 , $P < 0.001$). Additionally, the average VAS on postoperative 30 minutes, 3, and 6 hours were significantly less in the study group. The additional analgesic requirement in the first 24 hours postoperatively was significantly lower among patients in the study group than among those in the control group ($6 [7.8 \%$] vs $16 [21 \%$], $P = 0.021$). Total QoR-40 questionnaire scores were higher in patients who underwent bupivacaine.

CONCLUSION: Paracervical bloc with 5 % bupivacaine just before the TLH is an effective and safe procedure for reducing pain and the use of additional analgesia.

Keywords: Paracervical Block, Laparoscopic Hysterectomy, Randomized Trial

SS-05

Challenging Case of Long-standing Foreign Body Retention Within Vagina Resulting in Complications: A Multidisciplinary Approach

Yağmur Arslan¹, Oğuzhan Kuru², Yeliz Aykanat³

¹Department of Gynecology and Obstetrics, Istanbul University-Cerrahpasa, Istanbul Turkey

²Department of Gynecologic Oncology, Istanbul University-Cerrahpasa, Istanbul Turkey

³Department of Gynecologic Oncology, Adıyaman University, Adıyaman, Turkey

INTRODUCTION:: Foreign body retention within the vagina is a rare clinical scenario that presents unique challenges due to potential complications. We present a case study of a 56-year-old female patient with a prolonged history of retaining a perfume cap within the vagina since the age of 17, requiring a comprehensive multidisciplinary approach for evaluation and management. A detailed case history was obtained.

Imaging studies, surgical interventions, postoperative complications were documented.

CASE PRESENTATION: The patient was referred to our department due to Iron deficiency anemia and Postmenopausal bleeding. During examination, a foreign object was palpated at a depth of 2-3 cm within the vagina. Ultrasound examination showed a 10 mm endometrial thickness. Endometrial sampling could not be performed due to the obstruction caused by the foreign body in the vagina. Then, abdominal imaging (MRI and CT) was requested. After detailed discussion of the possible endometrial malignancy and the complication of the operation, a surgical procedure was planned. Total Abdominal Hysterectomy and Bilateral Salpingo-oophorectomy was performed. The frozen section of endometrium was benign. The perfume cap was pushed from the vaginal cavity and removed abdominally, because it could not be removed vaginally. During the expulsion of the foreign body, a suspicious 3 cm lesion in the vagina which was almost protruding into urinary bladder was detected. This mass was excised by partial cystectomy through posterior vaginal wall. Bladder repair and cystofix placement was done with the participation of the urology team. The patient was discharged on the 18th day postoperatively with the catheter and cystofix in place. However, on the 27th postoperative day, the patient was readmitted with a suspected cystofix infection. The urine culture and the cystofix cultures was positive. Appropriate antibiotic therapy was started by the Infectious Diseases.

A cystogram revealed the presence of a vesicovaginal fistula that a wide-caliber defect extending from the bladder neck to the vagina.

Four months later, a robotic vesicovaginal fistula repair by Urology team. A 2 cm defect was identified. The defective area was excised and repaired, and the patient was discharged with the cystofix and catheter. Six months after the second surgery, the patient presented with urinary incontinence complaints and underwent cystoscopy. A fistula orifice was observed on the right lateral aspect of the bladder base. A sensor guide was advanced through the fistula orifice, and it was observed to enter the vagina. A subsequent operation was planned.

CONCLUSION: In cases involving foreign body retention in the vagina, one of the most common complications are related to the urinary system. This case underscores the significance of a multidisciplinary approach in managing intricate cases of foreign body retention and its ensuing complications. Collaboration between gynecology, urology, and others was crucial in devising treatment strategies. The case emphasizes the necessity of meticulous preoperative assessment, comprehensive surgical planning, and vigilant postoperative care. A multidisciplinary approach, effective communication among specialties, and continuous patient monitoring are essential for achieving successful outcomes in such complex cases.

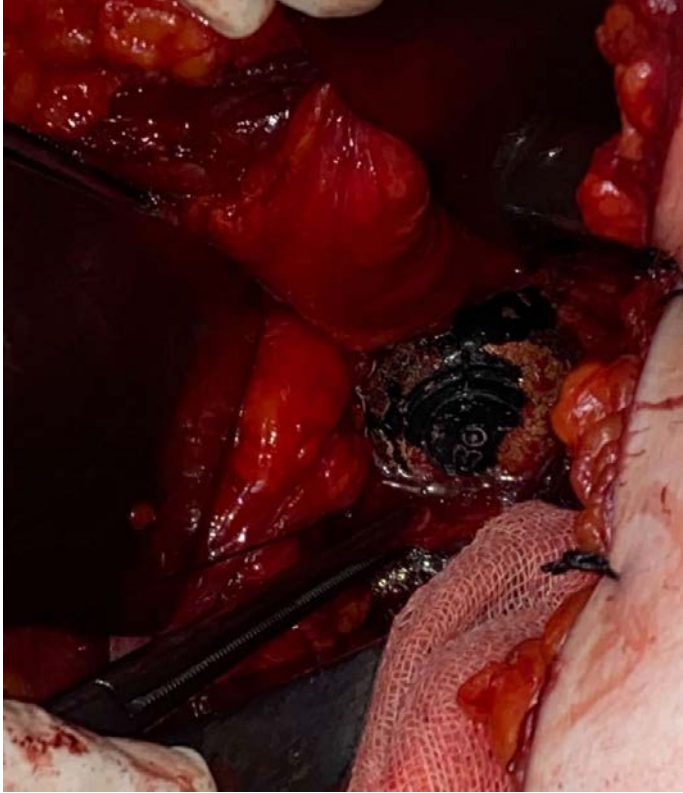Keywords: foreign body retention, vesicovaginal fistula, multidisciplinary approach, urinary tract complications,

Figure 1: Surgical Materials



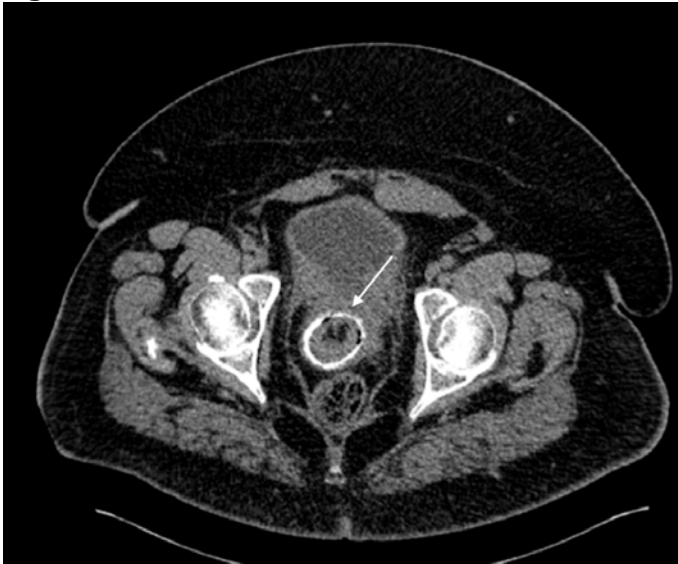Total Abdominal Hysterectomy-Bilateral Salpingoophorectomy materials and The Perfume Cap after its removed.

Figure 2: The Perfume Cap



The Perfume Cap before its removed

Figure 3: CT scan



The Perfume Cap at CT scan.

SS-06

Clear cell renal cell cancer in pregnancy: case report and literature overview

Ömer Toto¹, Özge Bitgen², Engin Çelik³

¹Tekirdağ Çerkezköy State Hospital, Tekirdağ, Turkey

²Nevşehir State Hospital, Nevşehir, Turkey

³Department of Gynecology Oncology, İstanbul Kanuni Sultan Süleyman Hospital, Health Sciences University, İstanbul

AIM: Urological cancers are very rare in pregnancy. The most reported of these is renal cell cancer. As with adnexal masses, they are usually discovered incidentally during routine ultrasonographic examination. In pregnancy, the diagnosis is made by ultrasonography at the first stage, and then magnetic resonance imaging is used to see the tumor type and extent. When deciding on surgery, the stage and aggressiveness of the cancer, the condition of the mother and fetus, and more importantly, the mother's request are taken into consideration. Depending on the stage of the cancer, radical nephrectomy or nephron-sparing surgery are the main treatments. Our aim in preparing this case report is to contribute to the roadmap to be created when renal tumors are encountered during pregnancy, in line with our experience.

METHOD: In this case report, we discussed our 38-year-old patient who was referred to us at 18 weeks of gestation with a preliminary diagnosis of adnexal mass. The mass of our patient was seen for the first time at the 8th gestational week, and she was referred to our clinic due to the enlargement of the mass during her follow-up. In the ultrasonography examination, a 14*10 cm solid mass was observed in the right adnexal area. In magnetic resonance imaging, the mass was thought to be of adnexal origin. There was no significant elevation in tumor markers. The operation was planned for the patient.

RESULTS: In the surgery, bilateral adnexa were normal. It was observed that the mass was located in the retroperitoneum and was of renal origin. Urologists were involved in the case. Right nephrectomy decision was made. One paraaortic lymph node was removed. The mass with the right kidney was sent to pathology during the operation. According to the frozen result, it was informed that a preliminary diagnosis could not be made and the main results would be determined after the paraffin evaluation. In the postoperative follow-up of our patient, there was no problem related to the operation and pregnancy. When she came to the follow-up examination with the final pathology results after discharge, it was seen that she was diagnosed with clear cell renal cell cancer. However, she was

5. Jinekoloji ve Obstetrikte Tartışmalı Konular Kongresi

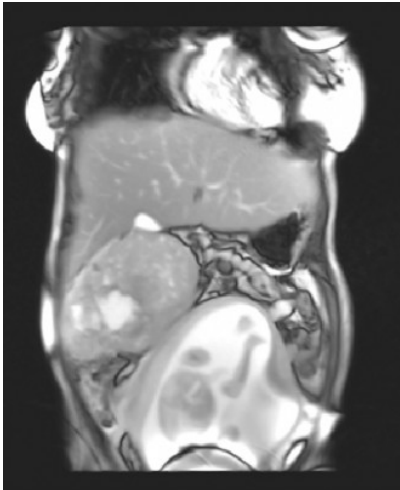
5-8 Ekim 2023 | Hilton Dalaman Sarıgerme

asked to be evaluated in an advanced center for a definitive diagnosis. Our patient was referred to a suitable advanced center for both the completion of the pathological evaluation and the follow-up and treatment of medical oncology.

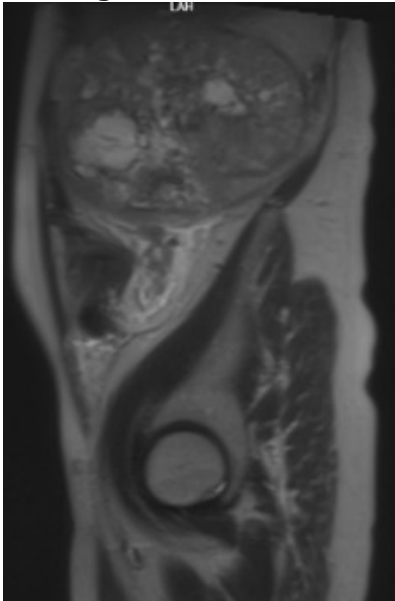
CONCLUSION: As a result, no consensus or guidelines have been proposed or validated for the treatment of kidney tumors in pregnant women. Surgical timing is individualized for each pregnant woman, taking into account maternal and fetal status, tumor stages, and the experience of the surgical team.

Keywords: pregnancy, renal cell cancer, renal masses

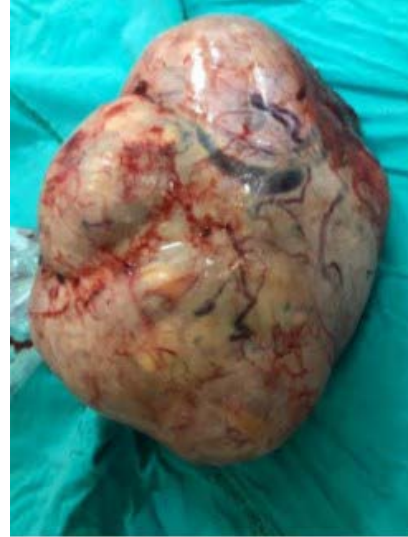MRI coronal section view of renal tumor and fetus.



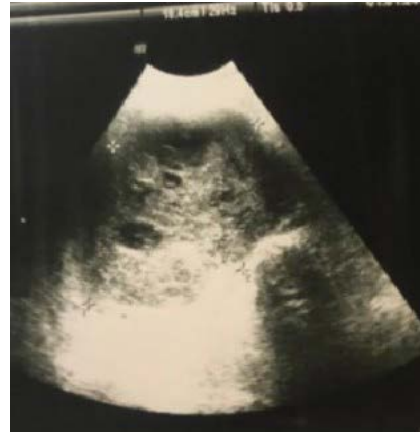MRI sagittal section of the renal tumor.



Renal mass removed with right kidney after right nephrectomy



Ultrasound image of the patient's mass during the examination performed by us at the 18th week of pregnancy.



SS-07

In the rare case of OHVIRA syndrome: Alternative treatment for hematocolpos

Seyma Dağlıtuncezdi Çam

Kayseri City Hospital, Kayseri, Turkey

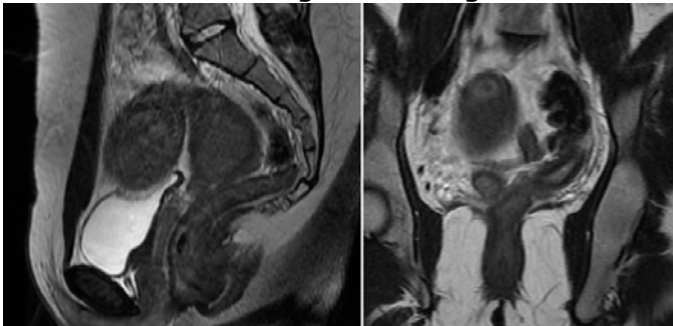
OBJECTIVE: OHVIRA (obstructive hemivagina and ipsilateral renal anomaly) syndrome is a rare congenital urogenital syndrome characterized by uterine didelphis, unilateral hemivagina with blind ending, and ipsilateral renal agenesis. Patients usually present with pelvic pain, pelvic mass, and dysmenorrhea symptoms related to hematocolpos that start after menarche. Patients are diagnosed with clinical, history and radiological imaging findings.

CASE: In this case report, we aimed to show the diagnosis of OHVIRA syndrome and an alternative approach to hematocolpos with percutaneous drainage in a 20-year-old virgin patient who presented with dysmenorrhea and chronic pelvic pain. In the ultrasonography of the patient, uterine didelphis, hematocolpos and right renal agenesis were observed. In the pelvic magnetic resonance imaging, the left uterus was normal and there was a hematometra of 10*6 cm in the right uterus. The patient did not accept the surgical procedure because she was a virgin. A percutaneous catheter was inserted by interventional radiology to drain the hematometra.

CONCLUSION: Although the primary treatment of OHVIRA syndrome is surgery, treatment of hematometra with percutaneous drainage can be considered, especially in virgin patients who do not accept surgery. This procedure may be preferred as a temporary treatment for pelvic pain.

Keywords: Hematocolpos, OHVIRA syndrome, percutaneous drainage, virgin

OHVIRA sendromlu olguda MR bulguları



SS-09

Outcomes of prenatally diagnosed fetal heterotaxy syndrome: A single tertiary center experience

Murat Çağan, Özgür Deren

Division of Perinatology, Department of Obstetrics and Gynecology, Faculty of Medicine, Hacettepe University, Ankara, Turkey

OBJECTIVE: The main aim of this study was to evaluate the type of associated anomalies and perinatal outcomes of fetuses with heterotaxy syndrome diagnosed prenatally on ultrasound.

METHODS: This was a retrospective case study conducted in the Division of Perinatology, Hacettepe University, over a period of three years from June 2020 to July 2023. Fetuses with ultrasound diagnosis of heterotaxy syndrome were included in the study. Heterotaxy was reported in prenatal ultrasound when there was abnormal thoracic or abdominal situs, detected with or without structural heart defects. The results of ultrasound examinations were re-evaluated and compared with fetal autopsy in suitable cases. The frequency of distribution of various components of situs abnormalities and associated cardiac defects were analyzed.

RESULTS: There were 10 fetuses diagnosed antenatally with heterotaxy syndrome. Of these, 5 had features of right atrial isomerism, 3 had features of left atrial isomerism. One fetus was diagnosed as isolated dextrocardia. No accompanying cardiac or non-cardiac abnormality was detected in the fetus, which was evaluated as situs inversus totalis. The most common concomitant cardiac pathology was pulmonary atresia and atrioventricular septal defect in patients with right and left atrial isomerism, respectively. Other cardiac anomalies were double outlet right ventricle, transposition of great arteries, and truncus arteriosus. Among the venous abnormalities, interrupted inferior vena cava with azygos continuation and persistent left superior vena cava were most common, followed by anomalous pulmonary venous connection. Persistent bradycardia or atrioventricular block was present in all cases of left atrial isomerism. While the left-sided spleen was present in one, asplenia was found in the remaining fetuses with right atrial isomerism. Five of the pregnancies were terminated due to major fetal heart defects. Autopsy examinations in these cases were consistent with prenatal ultrasound findings, except one intestinal malrotation, which was detected only by autopsy. Accompanying non-cardiac anomalies in fetuses with heterotaxy were a cleft lip and rocker bottom foot in one case each. No karyotype anomaly was detected in the chromosomal analysis. Two infants were diagnosed with primary ciliary dyskinesia during postnatal follow-up.



5. Jinekoloji ve Obstetrikte Tartışmalı Konular Kongresi

5-8 Ekim 2023 | Hilton Dalaman Sarıgerme

CONCLUSIONS: Accurate determination of viscerotri-atrial situs is essential because anomalies of situs are associated with a high prevalence of complex congenital heart disease and extra-cardiac anomalies. Although the severity of cardiac malformation seems to be the main determinant of the outcome, the possibilities of abnormal heart rhythm, intestinal malrotation, asplenia, and primary ciliary dyskinesia should also be kept in mind in predicting the prognosis.

Keywords: atrial isomerism, heterotaxy, situs ambiguous

SS-10

Contribution of Fetal Magnetic Resonance Imaging in Fetal Mild Ventriculomegaly

Umutcan Kayıkçı, Özgür Deren

Division of Perinatology, Department of Obstetrics and Gynecology, Faculty of Medicine, Hacettepe University, Ankara, Türkiye

AMAÇ: To evaluate the possible additional benefits of the Fetal MRI on Fetal Mild Cerebral Ventriculomegaly diagnosed with Fetal USG.

YÖNTEM: 48 Pregnancies with Fetal Cerebral Mild Ventriculomegaly with the atrial width range 10-15 millimeters were evaluated retrospectively. 48 Fetal US, 48 fetal MRI and 20 postnatal evaluation findings were compared.

BULGULAR: According to the Fetal US findings, amongst 48 Mild VMs, 26 were isolated and 22 were not. At 36 cases, ventricular width was between 10-12 mm and at 12 cases between 12,1-15 mm. At 26 out of 48 cases (54,1%), Fetal US and MRI were compatible but at 22 out of 48 cases (45,8 %), they were not. In the isolated VM group, at 17 out of 26 cases, Fetal MRI Confirmed Isolated VM, while at 9 cases MRI showed additional or different findings. At 8 out of 9, MRI showed cortical malformations and one case showed Corpus Callosum Dysgenesis additionally. In the non-isolated VM group, which was composed of abnormalities of posterior fossa, cysts, haemorrhage, calvarial bone abnormalities, at 8 out of 22 cases, Fetal MRI was compatible with Fetal US and at 14 out of 22 cases, MRI showed additional or different findings. Fetal MRI showed additional/different findings than fetal US in 34.6% of cases with isolated VM and 63.6% of the non-isolated VM cases. 20 cases' postnatal confirmations were made. Amongst 12 Fetal US/MRI compatible cases which have been evaluated postnatally; isolated group's, non-isolated group's and total postnatal confirmation ratios were 57, 100 and 75 percent, respectively (4/7, 5/5 and 12/12). In the Fetal US/MRI non-compatible cases, 8 postnatal

confirmations were made. Fetal US and MRI findings had postnatal confirmation ratios as 22 and 25 percent respectively (3/8 and 2/8).

SONUÇ: Fetal MRI showed additional/different findings than fetal US in 34.6% of cases with isolated VM and 63.6% of the non-isolated VM cases. In fetal cerebral mild ventriculomegaly cases, application of Fetal MRI has some additional benefits.

Keywords: mild ventriculomegaly, MRI, ultrasonography

SS-11

Evaluation of blood gas parameters of newborns with congenital heart disease: A Case-Control Study

Ayşe Çiğdem Bayrak, Edip Alptug Kir, Erdem Fadiloglu, Özgür Deren

Division of Perinatology, Department of Obstetrics and Gynecology, Faculty of Medicine, Hacettepe University, Ankara, Turkey

Objective: The aim of this study was to determine whether circulatory changes in fetuses with congenital heart disease (CHD) affect cord blood gas parameters and Apgar scores.

Study Design: This was a retrospective study of newborns with CHD diagnosed prenatally and comparable patients without a CHD diagnosis. Cord blood gas parameters and Apgar scores were evaluated in 68 infants with CHD delivered by cesarean section at 35-39+6 weeks of gestation. The distribution of cardiac anomalies was; 14 transposition of great arteries, 9 aortic coarctation, 7 pulmonary atresia / stenosis, 6 tetralogy of Fallot, 6 hypoplastic right heart syndrome, 5 hypoplastic left heart syndrome, 4 double outlet right ventricle, 4 ventricular septal defect, 3 Ebstein anomaly, 2 truncus arteriosus and 8 other structural cardiac anomalies. Control group consisted of 147 cases matched for maternal age, gestational week and birth weight. Non-parametric statistics were used with a $p < 0.05$ being significant.

Results: Median cord pH in CHD newborns was 7.30 and in controls it was 7.30. Median cord lactate was 1.6 in CHD and in controls it was 1.5 and base deficit was -0.4 to -0.9. p value was greater than 0.05 for all. 1., 5th and 10th minute Apgar scores were lower in the CHD group. 9 deaths in the CHD group at 6-month follow-up. When blood gas parameters and Apgar scores were evaluated in the CHD group, it was observed that there was no difference in Apgar scores and lactate between the ex group and the surviving group, but pH and base deficit were lower ($p:0.031$, $p: 0.004$). Furthermore, death was 0.62 times (38%) less likely with a 1-unit



5. Jinekoloji ve Obstetrikte Tartışmalı Konular Kongresi

5-8 Ekim 2023 | Hilton Dalaman Sarıgerme

increase in 1. minute Apgar score in this group.

Conclusions: In this study, CHD compared with healthy neonates; cord blood gas pH, lactate and base deficit values were similar for newborns with CHD and control group. However, APGAR scores for the first ten minutes were found to be significantly lower. In CHD group, ph value was higher and base deficit was lower for the newborns survived beyond 6 months compared to ones did not survive. This findings may help in the follow-up of these newborns, but randomized controlled trials in large patient groups are needed for clinical use.

Keywords: Apgar score, congenital heart disease, cord blood gas parameters

SS-12

Primary malignant melanoma of the cervix: A case report

Senanur Sönmez, İbrahim Yalçın
Department of gynecology and obstetrics, Ondokuz Mayıs University, Samsun, Turkey

Introduction background: Malignant melanoma is an aggressive cancer type that primarily manifests in the extremities and trunk. Less than 2% of all melanomas are associated with the female genital system. Among these genital involvements, vulvar-vaginal region is the most commonly affected, while occurrences in the ovary, uterus, and cervix are rare. Cervical malignant melanoma is extremely uncommon. The purpose of this study is to provide information about the diagnosis, follow-up, and treatment process of a patient diagnosed with cervical malignant melanoma.

Methods: The follow-up and treatment process of a patient diagnosed with cervical malignant melanoma is retrospectively presented in this study.

Findings: Our case is a 60-year-old female patient who presented with right groin pain and complaint of hyperpigmented area in the vagina. Examination revealed a hypoechoic area with dimensions of 20*13 mm in the uterocervical junction. Vaginal biopsy and cervical biopsy results concluded with infiltration of malignant melanoma. During the imaging, a hyperintense area that extended superiorly from the cervical canal and continued into the posterior cervical stroma drew attention. It was interpreted as a lesion invading the cervical stroma without extending beyond the cervix, and there were pathologically enlarged lymph nodes in the para-aortic, para-caval, and inter-aortocaval regions, indicating metastasis. Preoperative markers such as CA125, CA19-9, AFP, and CEA were within normal range in the patient. Radical hysterectomy, bilateral salpingo-oophorectomy, total vaginectomy, and pelvic para-aortic presacral lymph node dissection

were performed on the patient. The operative material was diagnosed as malignant melanoma, with metastatic lymph nodes showing positive staining for HMB45, MART1, S100, and SOX10.

Results: Cervical malignant melanoma is a rare condition. It can be symptomatic but can also be incidentally detected. Diagnosis is established through immunohistochemical examinations. Surgical treatment constitutes the mainstay of the treatment plan for malignant melanoma. Radical hysterectomy, pelvic lymph node dissection, and partial vaginectomy are commonly performed. Our case underwent radical hysterectomy, bilateral salpingo-oophorectomy, total vaginectomy, and pelvic para-aortic presacral lymph node dissection. It is known that postoperative adjuvant immunotherapy prolongs disease-free survival and that adjuvant immunotherapy + chemotherapy also extends both disease-free and overall survival. In our case, it was deemed appropriate for the patient, evaluated in the postoperative period, to receive radiotherapy, chemotherapy, and subsequently immunotherapy in order to prolong survival.

Keywords: cervix, malignant, melanoma, primary

SS-14

Aggressive Angiomyxoma of the Vulva: an uncommon case report

Ayşegül Elmas¹, Melis Ozbilen¹, ESRA KELES²

¹University of Health Sciences Turkey, Kartal Dr Lutfi Kırdar City Hospital, Department of Obstetrics and Gynecology, Istanbul, Turkey

²University of Health Sciences Turkey, Kartal Dr Lutfi Kırdar City Hospital, Department of Gynecologic Oncology, Istanbul, Turkey

INTRODUCTION: Vulvar aggressive angiomyxoma is a rare, locally invasive mesenchymal tumor occurring usually in women of reproductive age. Due to its slow-growing nature, it is often overlooked and misdiagnosed. Herein, we describe a case report of vulvar aggressive angiomyxoma in a 47-year-old woman presenting with a large pedunculated swelling on the right labia majora who underwent complete surgical excision of the neoplasm.

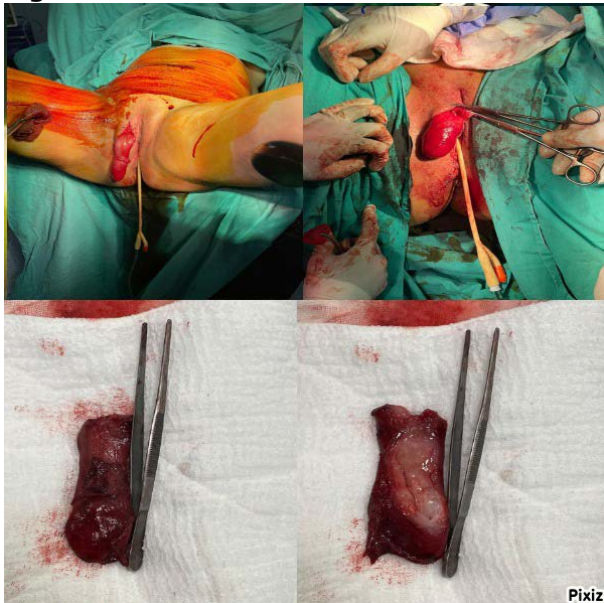
CASE: A 47-year-old female presented with a slow-growing mass on the right labia majora. Local examination showed a well-circumscribed pedunculated polypoidal mass measuring 7.2 cm × 5 cm × 2.2 cm. The mass was non-tender, soft and spongy in consistency. [Figure 1]. The inguinal lymph nodes were not enlarged. Her blood investigations and sonography of the abdomen revealed no abnormality. The patient was referred to gynaecology services for excisional biopsy of the lesion considering a diagnosis of a vulvar abscess/

neoplasm/cyst or a bartholin abscess. She underwent a local excision of the tumor. The final histopathology revealed that the tumor was composed of spindle and stellate-shaped cells in a myxoid matrix. These cells had eosinophilic cytoplasm and lacked significant nuclear pleomorphism, mitosis and necrosis. This was suggestive of aggressive angiomyxoma.

DISCUSSION: Aggressive angiomyxoma is a slow-growing vulvovaginal mesenchymal neoplasm with a marked tendency for local recurrence, but with a low tendency to metastasize. It involves mainly the pelvis, vulva, perineum, vagina and urinary bladder in adult women in the reproductive age. Considering its locally aggressive nature, appropriate management and long-term follow-up is necessary. Many options for the treatment of recurrences have been tried with varying success, but no single modality is clearly beneficial over others. Aggressive angiomyxoma may be misdiagnosed clinically, as Bartholin cyst, lipoma, labial cyst, Gartner duct cyst, levator hernia or sarcoma. Fibro-epithelial stromal polyp, superficial angiomyxoma, angiofibroma, cellular angiofibroma and smooth muscle tumors also need to be considered in the differential diagnoses of a bartholin cyst in the perineum. Our patient was not subjected to radiological investigation as its clinical appearance at presentation was that of a bartholin cyst. Wide surgical excision is the traditional treatment of choice. Recurrences may occur from months to several years after excision (2 months to 15 years). As late recurrences are known, all patients need to be counselled about the need for long-term follow-up. Many options for the treatment of recurrences have been tried with varying success, but no single modality is clearly beneficial over others.

Keywords: Aggressive angiomyxoma, mesenchymal tumor, vulval tumor

Figure 1



polypoidal mass measuring 7.2 cm x 5 cm x 2.2 cm on the right labia majora

SS-15

A rare case report: uterine angioleiomyoma

Kübra Sevinç, Fazıl Avcı, Özlem Seçilmiş, Çetin Çelik
Selcuk University Faculty of Medicine, Department of Obstetrics and Gynecology, Konya, Turkey

AIM: We aimed to present a 66-year-old case of uterine angioleiomyoma diagnosed after admission due to chronic pelvic pain.

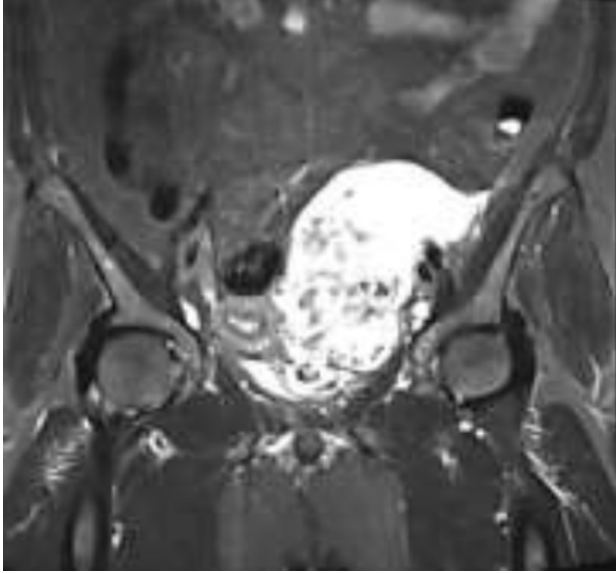
MATERIAL-METHODS: The characteristics, gynecologic examination, laboratory tests, imaging method, surgical method and pathology results of a patient who applied to the clinic with chronic pelvic pain were evaluated.

CASE: At the age of 66, she applied to the clinic with the complaint of chronic pelvic pain. The mass observed on transvaginal ultrasonography filled the left adnexal area and extended towards the douglas. Laboratory tests reported that hemoglobin was reported as 11.8g/dl and CA-125 level as 9.6 U/ml (normal<35U/ml). Endometrial curettage biopsy result was reported as mucinous material and fragments of endometrial superficial epithelium. Pelvic Magnetic Resonance imaging result "A mass extending from the left adnexal area to douglas was followed. In the central part of the mass, there were cystic components in the periphery and central, with hypointense solid components being more prominent in the periphery on T1 and T2-weighted images. A mass of approximately 11x9.5x12 cm was observed. Contrast enhancement in solid components after contrast agent injection to the mass followed. Degenerated myoma showing hyalinization was considered primarily in the diagnosis. It was reported as compression on the left lateral of the bladder due to mass compression" (Figure A, B, and C). Hysterectomy and bilateral salpingoopherectomy were planned. In the observation, a multinodular, off-white mass measuring 13x12x5 cm, attached to the lower segment of the uterus by a fibrous band, was observed (Figure 2). The pathology reported as angioleiomyoma. Cells forming the lesion were reported immunohistochemically as SMA, Desmin and Kaldesmon positive, vascular structures were reported as CD 34 positive and D2-40 negative.

CONCLUSION: In the differential diagnosis of uterine masses; angioleiomyomas that are rare, benign and have a good prognosis should also be considered. The surgical decision can be individualized according to the patient's complaint, the position of the mass, age and fertility status.

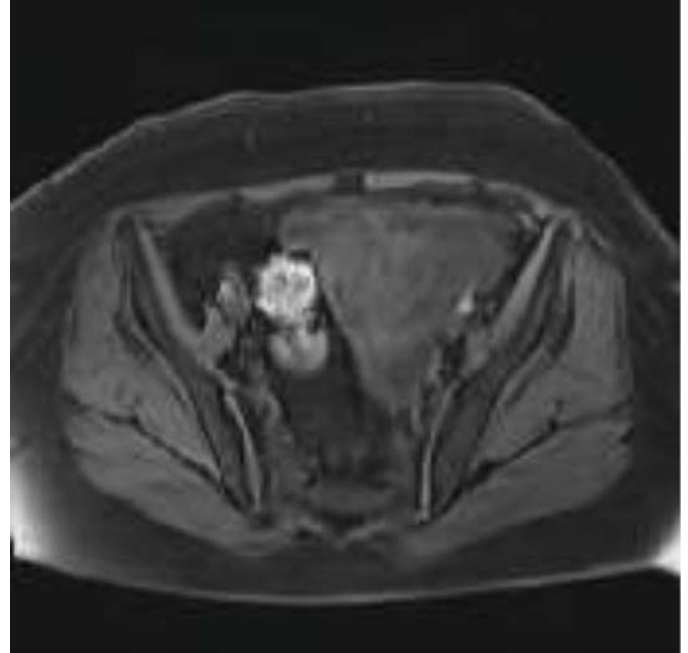
Keywords: angioleiomyoma, surgery, tumor, uterine

Figure 1



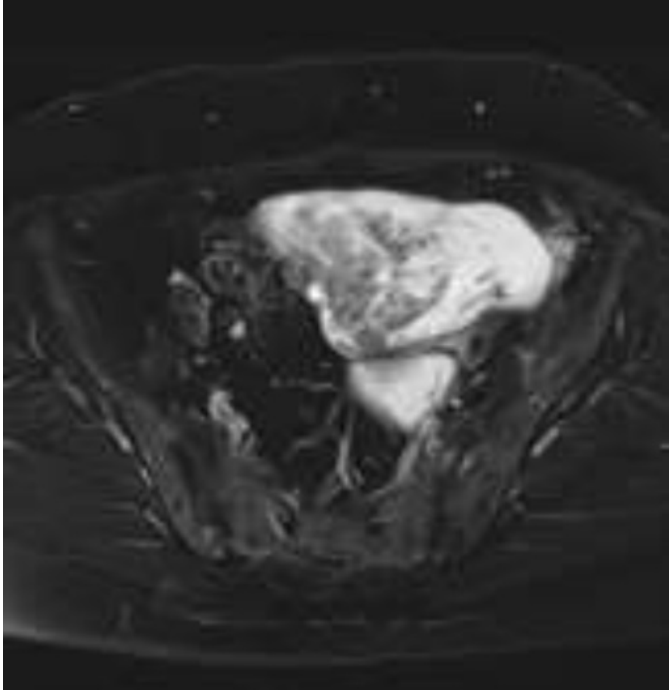
A mass of approximately 11x9.5x12 cm was observed (C).

Figure 1



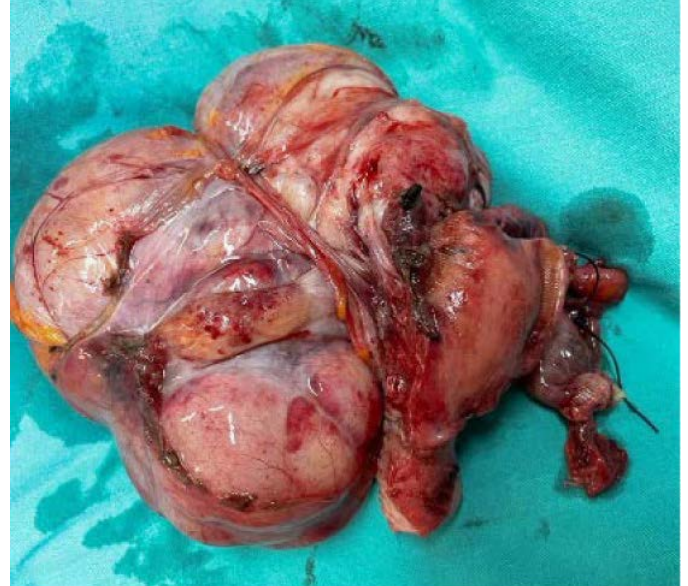A mass extending from the left adnexal area to Douglas was followed (A).

Figure 1



In the central part of the mass, there were cystic components in the periphery and central, with hypointense solid components being more prominent in the periphery on T1 and T2-weighted images (B)

Figure 2



An off-white mass measuring 13x12x5 cm with multinodular appearance



5. Jinekoloji ve Obstetrikte Tartışmalı Konular Kongresi

5-8 Ekim 2023 | Hilton Dalaman Sarıgerme

SS-17

Investigation of the effect of the perioperative nutritional risk index on the quality of life, wound healing and well-being of the cases

Fazıl Avcı¹, Günay Safarova¹, Kübra Sevinç¹, Memduha Aydın², Cetin Çelik¹, Ahmet Bilgi¹

¹Selcuk University Faculty of Medicine, Department of Obstetrics and Gynecology, Konya, Turkey

²Selcuk University Faculty of Medicine, Department of Psychiatry, Konya, Turkey

AIM: We aimed to investigate the effect of the perioperative nutritional risk index on the quality of life, wound healing and well-being of the patients.

MATERIAL-METHOD: 137 patients who were hospitalized and operated on Selcuk University Faculty of Medicine, Gynecology and Gynecological Oncology service were included in this prospective study. The cases were divided into two groups as low-risk group 1 (score <3) and high-risk group 2 (≥ 3) according to the NSR 2002 (1) nutritional index. Demographic and clinical characteristics of the cases (age, height, weight, body mass index, fever, pulse, blood pressure, respiratory rate, upper arm circumference, triceps skinfold thickness, marital status, educational status, smoking and alcohol use, chronic disease history (Diabetes Mellitus, Hypertension and other), working status, surgical and pathologic features (benign, malignant, incision type (transverse vertical and laparoscopic), subcutaneous closure (single and multi-layer), suture material (prolene and stapler), incision status (incision healing time, infection, dehiscence), corset use, ECOG performance score and preoperative laboratory values (hemoglobin level, platelet count, white cell count, neutrophil count, lymphocyte count, mean platelet volume, C-reactive protein, blood urea nitrogen, creatinine, aspartate aminotransferase), alanine aminotransferase, uric acid, triglyceride, cholesterol, thyroid stimulating hormone, ferritin level) were evaluated. The Hospital Anxiety and Depression Scale (14 questions) (2), NSR 2002 form and Quality of Life Form (30 questions) (3) were evaluated. A questionnaire form was filled. The data were evaluated statistically.

RESULTS: A total of 137 cases, 124 cases in group 1 and 13 cases in group 2, were evaluated in the study. A statistically significant difference was found between the two groups in terms of demographic and clinical characteristics, upper arm circumference and triceps skin fold ($p=0.001$ and $p=0.008$, respectively) (Table 1). When the two groups were compared according to surgical characteristics and laboratory results, a

significant difference was found in terms of wound healing time, wound complications and serum albumin levels ($p=0.003$, $p=0.001$, and $p=0.008$, respectively, Table 2). There was no significant difference between the two groups in terms of anxiety and depression scores ($p>0.05$, Table 3). High well-being and moderate quality of life were found in both groups, and there was no statistical difference between them. Between the two groups, fatigue ($p=0.003$), nausea and vomiting ($p=0.010$), pain ($p=0.009$), dyspnea ($p=0.001$), insomnia ($p=0.015$), loss of appetite ($p=0.001$) and diarrhea (A statistically significant difference was found in terms of $p=0.041$). In the correlation analysis of the factors that significantly affected the NSR 2002 risk scoring between the two groups, there was a positive correlation between wound complication ($p=0.001$), wound healing time ($p=0.003$), and upper arm circumference ($p=0.001$), triceps skinfold thickness ($p=0.008$).) and serum albumin levels ($p=0.006$) were negatively correlated.

CONCLUSIONS: The nutritional status determined in the preoperative period affects the well-being of the patients in the perioperative and postoperative period. Nutritional support to be applied in the perioperative period will positively affect the perioperative and postoperative recovery of the cases and reduce operative morbidity.

Keywords: HAD scale, quality of life scale, NSR 2002, wound



5. Jinekoloji ve Obstetrikte Tartışmalı Konular Kongresi

5-8 Ekim 2023 | Hilton Dalaman Sarıgerme

Comparison of cases according to HAD and EORTC QLQ-C30 quality of life scale

		Group 1 (n=124)	Group 2 (n=13)	P value
HAD scale form	Depression	9,6±3,4	10,3±3,5	0,497
	Anxiety	10,5±3,6	11,4±3,2	0,378
EORTC QLQ-C30 Quality of Life scale				
	Item			
Functional status *0-100				
Physical function	1-5	45,5±17,5	40,5±14,0	0,481
Role function	6-7	45,0±25,0	46,3±17,5	0,920
Emotional function	21-24	31,5±12,0	32,0±13,0	0,848
Cognitive function (cognitive)	20,25	46,3±18,8	45,0±16,3	0,874
Social function	26-27	43,8±17,5	43,8±18,0	0,882
General well-being**0-100	29-30	79,3±12,1	72,1±15,7	0,054
Symptom scale***0-100*				
Weakness	10,12,18	37,4±15,0	59,8±26,6	0,003
Nausea and vomiting	14-15	30,0±10,0	46,3±26,3	0,010
Pain	9,19	37,5±16,3	56,3±28,8	0,009
Dyspnea	8	32,5±15,0	45,0±25,0	0,001
Insomnia	11	37,5±20,0	57,5±32,5	0,015
Loss of appetite	13	35,0±15,0	62,5±32,5	0,001
Constipation	16	32,5±15,0	37,5±25,0	0,254
Diarrhea	17	30,0±12,5	37,5±17,5	0,041
Financial difficulty	28	35,0±17,5	35,0±12,5	0,979

Table 3

Comparison of the cases according to their demographic and clinical characteristics

Variables		Group 1 (n=124)	Group 2 (n=13)	p value
Age	year	57,1±9,0	56,2±14,0	0,748
Gravida		3 (0-8)	4 (0-7)	0,262
Parity		3 (0-8)	3 (0-7)	0,586
BMI	kg/m2	31,2±6,2	28,6±5,2	0,152
Fever	degree	36,6±0,3	36,5±0,3	0,898
Heart rate	minute	83,5±10,1	86,4±6,2	0,306
Respiratory rate	minute	16,8±1,6	16,5±1,6	0,518
Blood pressure	systole	116,2±9,7	114,6±4,8	0,586
Blood pressure	diastole	72,7±7,3	70,8±7,3	0,371
Upper arm circumference	mm	32,4±4,1	27,0±2,2	0,001
Triceps skinfold	mm	20,7±4,4	17,2±4,0	0,008
Marital status	Single	3	2	0,133
	Married	118	11	
	Widow	3	0	
Cigarette use	Yes	10	1	0,720
	No	114	12	
Alcohol	Yes	7	1	0,489



5. Jinekoloji ve Obstetrikte Tartışmalı Konular Kongresi

5-8 Ekim 2023 | Hilton Dalaman Sarıgerme

	No	117	12	
Education status	Illiterate	17	2	0,682
	Primary school	87	8	
	Middle school	6	1	
	High school	7	1	
	University	7	1	
Coexisting disease	DM	28	4	0,177
	HT	19	1	
	Other	13	4	
	No	64	4	
Work status	Yes	8	1	0,604
	No	116	12	

Table 1

Comparison of the cases according to their surgical characteristics and laboratory results

Variables		Group 1 (n=124)	Group 2 (n=13)	P value
Pathology	Benign	48	6	0,405
	Malign	76	7	
Type of surgical incision	Vertical	35	6	0,260
	Transvers	67	4	
	Laparoscopic	22	3	
Subcutaneous closure	One layer suture	40	5	0,432
	Multiple layer suture	84	8	
Suture material	Prolene	91	7	0,124
	Others	33	6	
Corset use	Yes	43	8	0,056
	No	81	5	
Wound healing	Day	9,6±2,1	11,5±1,8	0,003
Wound complication	Infection	1	6	0,001
	Wound dehiscence	3	1	
	No	120	6	
Hb	g/dL	12,4±2,1	12,1±1,1	0,529
PLT	K/ μ L	308,3±91,5	331,0±84,0	0,394
WBC	K/ μ L	9,8±3,7	9,4±3,5	0,700
Neutrophyl count	K/ μ L	7,2±4,0	7,0±3,8	0,865
Lymphocyte count	K/ μ L	1,8±1,0	1,7±1,0	0,923
MPV	fL	10,2±1,0	10,2±0,8	0,978
CRP	mg/L	8,4±3,4	7,8±3,6	0,558
Bun	mg/dL	26,5±9,6	24,4±8,6	0,443
Cr	mg/dL	0,7±0,1	0,6±0,1	0,363
AST	U/L	19,3±8,3	18,1±5,8	0,607
ALT	U/L	15,8±7,5	17,1±10,0	0,571
TSH	μ IU/L	2,8±2,2	2,5±1,2	0,639
Ferritin	mg/L	85,1±81,0	85,0±63,1	0,995
Albumin	g/dL	3,7±0,6	3,2±0,6	0,008



5. Jinekoloji ve Obstetrikte Tartışmalı Konular Kongresi

5-8 Ekim 2023 | Hilton Dalaman Sarıgerme

Table 2

Correlation analysis of factors affecting NSR 2002 risk scoring

		r value	p value
Wound complication		0,549	0,001
Wound healing time	Days	0,251	0,003
Upper arm circumference	mm	-0,368	0,001
Triceps skinfold thickness	mm	-0,226	0,008
Albumin level	g/dL	-0,225	0,008

Table 4

SS-18

Endometrial cancer sentinel lymph node mapping: single center experience

Fazıl Avcı, Ahmet Bilgi, Çetin Çelik
Selcuk University Faculty of Medicine, Department of Obstetrics and Gynecology, Konya, Turkey

AIM: We aimed to present the sentinel lymph node mapping in endometrial cancer.

MATERIAL-METHODS: 137 cases with a diagnosis of endometrial cancer whose sentinel lymph node was performed between 5.01.2017 and 27.03.2023 in the Department of Gynecological Oncology, Faculty of Medicine, Selcuk University were included. Cervical injection technique was used for sentinel lymph node application (1). Sentinel pelvic and paraaortic lymph node dissection was performed by applying indocyanine green agent to the cases evaluated preoperatively. Lymph node dissection was also performed from palpable lymph nodes in the cases. Hematoxylin eosin and pancytokeratin staining were used for pathological evaluations. Age, surgical and pathological data of the cases were evaluated statistically.

RESULTS: The mean age of 137 cases was calculated as 59.2±8.6 years, and 83.9% of the cases were found in the postmenopausal period (Table 1). It was calculated that 89.1% of the cases were at stage 1, 91.2% were endometrioid type, and 93.7% were grades 1 and 2. Tumor size ≤20 mm was detected in 56.2% of 77 cases. Myometrial invasion <50% was detected at a rate of 91.2%. LVSI was detected in 6 (4.4%) cases and BPLND was performed in 81.8%. Sentinel staining was observed in 131 cases (95.6%). Sensitivity for detecting sentinel lymph node was 83.3%, specificity was 3.6%, positive predictive value was 3.6%, and negative predictive value was 83.3%. Lymphatic metastases were detected in 6 cases, while 4 of them were macrometastases and 2 of them were isolated tumor cells. As lymphatic metastases, both sentinel and

non-sentinel positivity were detected in 2 cases, sentinel positive non-sentinel negativity in 3 cases, and sentinel negativity and non-sentinel positivity in 1 case (Table 2). Recurrence was detected in 4 cases. Sentinel staining was bilateral in three and unilateral sentinel staining in one of the recurrent cases. No lymphatic metastases were reported in any of them. It was detected as stage 1A and endometrioid histological type in 4 cases (Table 3). KT was applied to 2 of the recurrences, surgery to 1, and KT+ surgical treatment to 1 of them. Adjuvant treatment was not applied to 67.9% of the cases. The 3-year disease-free survival and overall survival of the cases were calculated as 16.1 (1-69) and 16.1 (1-69) months, respectively.

CONCLUSION: Sentinel lymph node application is a safe method and is successfully applied in low-risk endometrial cancer.

Keywords: endometrial cancer, lymphatic metastasis, recurrence, sentinel lymph node

Characteristics of cases diagnosed with endometrial cancer

Variables		(n=137)	(%)
Age	year	59,2±8,6	
Menopausal status	Premenopausal	22	16,1
	Postmenopausal	115	83,9
Stage	Stage 1	122	89,1
	Stage 2	6	4,4
	Stage 3	81	5,9
	Stage 4	1	0,7
Histological type	Endometrioid	125	91,2
	Serous	9	6,6
	Clear cell	1	0,7
	Mixt	1	0,7
	Mucinous	1	0,7
FIGO Grade	Grade 1	101	73,7
	Grade 2	20	20,0
	Grade 3	16	16,0
Tumor size, mm	≤20	77	56,2
	>20	66	43,8
Myometrial invasion	No	18	13,1
	<%50	107	78,1
	>%50	12	8,8
Mayo risk score	Low risk	31	22,6
	High risk	106	77,4
LVSI	Yes	6	4,4
	No	131	95,6
Lymphadenectomy	SLND	7	5,1
	BPLND	112	81,8
	BPPALND	18	13,1
Cervical stromal invasion	Yes	15	11,0
	No	122	89,0

Tablo 1



5. Jinekoloji ve Obstetrikte Tartışmalı Konular Kongresi

5-8 Ekim 2023 | Hilton Dalaman Sarıgerme

Distribution of recurrent cases

	Sentinel mapping	lymphatic metastasis	Stage	Histological type
Case 1	Bilateral	No	1A	Endometrioid
Case 2	Bilateral	No	1A	Endometrioid
Case 3	Bilateral	No	1A	Endometrioid
Case 4	Unilateral	No	1A	Endometrioid

Table 4

Recurrence, lymph node status, adjuvant treatment results of the cases

		(n=137)	(%)
Recurrence	Yes	4	2,9
	No	133	97,1
Recurrence localization	Pelvic center	1	0,7
	Lateral pelvic	1	0,7
	İntraabdominal	2	1,5
	No	133	97,1
Recurrent treatment	Chemotherapy	2	1,5
	Surgery	1	0,7
	Chemotherapy plus surgery	1	0,7
	No	133	97,1
Number of pelvic lymph nodes		15 (1-62)	
Number of paraaortic lymph nodes		1 (1-10)	
Sentinel staining	No	6	4,4
	Unilateral	23	16,8
	Bilateral	108	78,8
	At least one	131	95,6
Lymphatic metastasis	Yes	6	4,4
	No	131	95,6
Sentinel positivity	Yes	5	3,6
	No	132	96,4
Lymphatic metastasis type	Macrometastasis	4	
	Isolated tumor cell	2	
Adjuvant therapy	No	96	67,9
	Brachytherapy	16	11,7
	Chemotherapy	5	3,6
	Chemotherapy plus radiotherapy	20	14,6
	Brachytherapy plus EBRT	3	2,2

Table 2

Sentinel and non-sentinel lymph node distribution in lymphatic metastases

	Sentinel	Non-sentinel
Case 1	+	+
Case 2	+	+
Case 3	+	-
Case 4	+	-
Case 5	+	-
Case 6	-	+

Table 3



5. Jinekoloji ve Obstetrikte Tartışmalı Konular Kongresi

5-8 Ekim 2023 | Hilton Dalaman Sarıgerme

SS-19

Management of simultaneous pancreatic cancer in a cervical cancer patient undergoing pelvic exenteration

Süle Ütü, İbrahim Yalçın

Department of gynecology and obstetrics, Ondokuz Mayıs University Samsun, Turkey

Objectives: Cervical cancer is diagnosed in over 529,000 new cases annually, with a mortality rate of more than 50%, making it the second most common cause of cancer related morbidity and mortality in women globally. In cervical cancer, pelvic exenteration is a potentially curative surgical procedure for patients with central cervical cancer recurrence (involving the vaginal apex or pelvis) after primary radiation therapy or surgery followed by radiation therapy, provided that complete treatment is achieved. The co-occurrence of cervical cancer and pancreatic cancer is rarely observed. The aim of this study is to provide information about the diagnosis, follow up, and treatment process of a patient with simultaneous pancreatic cancer in a cervical cancer patient who underwent pelvic.

Method: The diagnosis, follow up, and treatment process of a patient diagnosed with simultaneous pancreatic cancer in a cervical cancer patient who underwent pelvic exenteration are presented retrospectively.

Findings: A 55 year old female patient presented to us with post-coital vaginal bleeding. The cervical biopsy revealed endocervical adenocarcinoma. Abdominal MRI (magnetic resonance imagination) imaging revealed a hypovascular mass lesion measuring 4x3 cm, extending from the internal os towards the lower uterine segment, causing parametrial invasion in the cervix. Lymph nodes with dimensions of 14x11 mm on the right and 15x10 mm on the left were observed in both iliac chains.

The patient received curative radiation therapy to the pelvis at 50.4 Gy (gray), 5 cycles of cisplatin at 40 mg/m², and 7 Gy (gray) * 3 fractions of intracavitary brachytherapy. Follow up magnetic resonance imagination imaging after radiotherapy and brachytherapy showed that compared to the previous examination, the mass in the cervix had regressed, but a residual mass around the canal was still present.

On the follow up imaging, a predominantly solid mass measuring approximately 27x20 mm with lobulated contours, including cystic components in the superior and inferior segments, was identified in the head of the pancreas. Furthermore, due to the observation of predominantly left-sided masses with a similar character, measuring approximately 22x15 mm, including cystic components, in the central section of the pancreatic

body, a pancreatic biopsy was performed. The biopsy result indicated a pancreatic cystic epithelial neoplasm

The patient underwent pelvic exenteration. The operative material confirmed endocervical adenocarcinoma.

Following surgery, systemic chemotherapy was administered, and surgery was planned for the pancreatic mass. After receiving 6 cycles of carboplatin and paclitaxel, a pancreaticoduodenectomy was performed. The operative material revealed a high-grade intraductal papillary mucinous neoplasm.

Conclusion: In cervical cancer, pelvic exenteration is a potentially curative surgical procedure for patients with central cervical cancer recurrence (involving the vaginal apex or pelvis) after primary radiation therapy or surgery followed by radiation therapy, provided that complete treatment is achieved. The co-occurrence of cervical cancer and pancreatic cancer is quite rare. Traditional surgery for pancreatic head cancer or the uncinat process involves pancreaticoduodenectomy. In our case, simultaneous pancreatic cancer was detected with cervical cancer. After pelvic exenteration due to cervical cancer, it was deemed appropriate to administer systemic chemotherapy to the patient and perform a pancreaticoduodenectomy following systemic chemotherapy.

Keywords: cervical, cancer, exenteration, pelvic

SS-20

Case Report: Heterotopic Pregnancy

Meziha Taşyürek

University of Health Sciences Turkey, Kartal Dr Lutfi Kırdar City Hospital, Department of Obstetrics and Gynecology, Istanbul, Turkey

Heterotopic pregnancy is the simultaneous occurrence of intrauterine pregnancy and ectopic pregnancy. The patient who consulted to our outpatient clinic with the complaint of vaginal bleeding was observed to have an intrauterine pregnancy with a disrupted sac and fetal heartbeat in the right tubal region. The operation was planned before the patient clinical condition worsened. Laparoscopically, the pregnancy material in the tubal region was removed and the intrauterine disrupted gestational sac was curetted. In this case report, I will discuss heterotopic pregnancy, a condition that can cause acute abdomen and suddenly deteriorate the patient clinical condition.

Keywords: heterotopic pregnancy, ectopic pregnancy, acute abdomen

SS-21

A urachal leiomyoma misdiagnosed as an ovarian tumor:an extremely rare case presentation

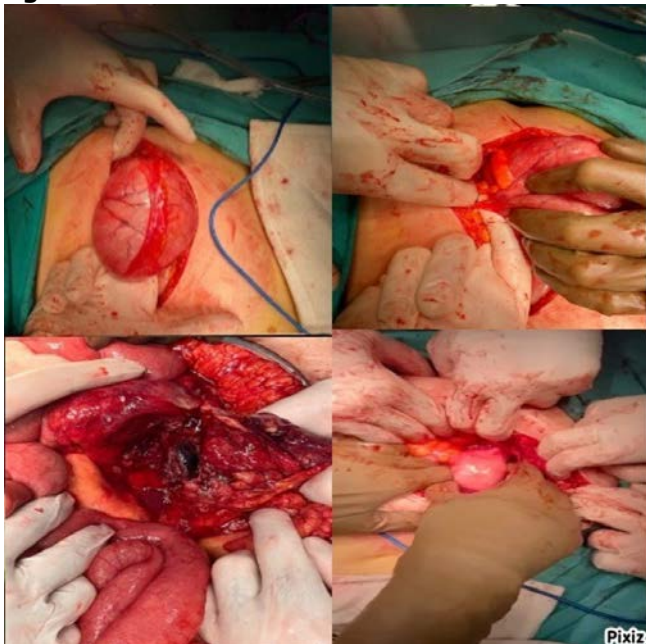
Melis Özbilen

Kartal Dr.Lütfi Kırdar City Hospital,İstanbul

Although the urachus is an embryonic structure, it can be found in approximately 2% of adults (1,2). In cases in which disappearance of the urachus fails completely, leakage of urine through the umbilicus is diagnosed soon after birth. In cases of partial obliteration, the urachal remnant remains asymptomatic until infection develops (3). Leiomyomas are benign genital tumors mainly composed of smooth muscle cells and a varying amount of connective tissue. Extra-uterine leiomyomas are rare and may occur in the lungs, ovaries, peritoneum, breast, esophagus, and stomach. When the leiomyoma of the uterus is large enough, it can cause lower abdominal pain. The treatment is complete surgical excision of the tumor. Further, when the urachus communicates with the bladder, a cuff, at least of the muscularis, should be excised around the bladder attachment (4). The classical route of approach is suprapubic. Complete surgical excision is the strategy to prevent recurrence and malignant degeneration. A close follow up in these patients is important.

Keywords: Urachus, Leiomyoma, urachal myoma

figure 1



SS-22

Analysis of uterine ruptures, tertiary center experience

Alev Esercan

Department of Obstetrics and Gynecology, Sanliurfa Education and Training Hospital, Sanliurfa, Turkey

Uterine rupture is the rupture of the uterine wall during delivery or pregnancy, and when the rupture extends into the uterine serosa it may extend into the bladder or broad ligament. It can cause massive bleeding and cause maternal mortality and fetal asphyxia/neonatal death. While maternal fatality rate is 33% in the literature, perinatal mortality is 52%. Among the risk factors, increased number of cesarean sections, high birth weight, having received induction, and trying of labour after cesarean section (TOLAC) can be counted. While the prevalence in the literature is 1.9-5.9/10.000 births, this rate varies between 1.4% and 16.68 in Ethiopia. We aimed to examine the cases in detail, considering that the prevalence of uterine rupture may reflect our country, as our hospital is the hospital with the highest number of births in Turkey (average 27 thousand births/year). From the surgical records of the last 5 years, the data of patients with uterine rupture who underwent hysterectomy were obtained. In the last 5 years, 23 patients had hysterectomy due to rupture, and 5 patients had a history of pregnancy termination after previous cesarean section. When the remaining 18 patients were examined in detail, the mean age was 34.11 ± 3.62 (27-41) years, and 50% of the patients had uterine rupture after normal delivery. The mean cesarean section number of patients who had cesarean section was 3.5 ± 1.33 (1-5), mean gravida of the patients was 6.22 ± 2.92 (2-13), and mean parity was 4.33 ± 2.61 (0-10) births. While 10 of the 18 patients had ruptures from the anterior wall and incision line, 1 ruptured from the posterior wall, 6 from the right side wall, and 1 from the left side wall. Placental adhesion anomaly was detected in 6 of 9 patients with a history of cesarean section. Bladder perforation was detected simultaneously with the rupture in 5 patients. 2 patients arrived in arrest and died despite hysterectomy and interventions. As seen, having a history of cesarean section, grandparity, and not using partograph increase uterine rupture. In our study, rupture was observed in patients who had a cesarean section and in patients with high parity. Since only patients who underwent hysterectomy due to rupture were evaluated in our study, the entire prevalence cannot be calculated. Some patients are followed up with repairs due to rupture. When looked at, increasing placental adhesion anomalies due to multiple cesarean sections complicate patients. 2 ex patients had placental adhesion anomaly. If there is a history of cesarean section while operating the cases, this should be considered and an experienced team should be formed accordingly.

Keywords: grandparity, placental adhesion anomaly, uterine rupture

SS-23

A rare case diagnosed at birth, Approach to the association of pregnancy and cervical intraepithelial neoplasia

Huriye Güvenc Sacıntı, Ramazan Erda Pay, Caner Köse, Tahir Eryılmaz
Etlik City Hospital, Gynecology and Obstetrics Service

INTRODUCTION: Cervical intraepithelial neoplasia (CIN) is a premalignant squamous lesion of the uterine cervix, caused by human papilloma virus (HPV) infection, the most common sexually transmitted infection in women. In recent years, the incidence of cervical dysplasia diagnosed in pregnant women has substantially increased which is related to a general increase in the prevalence of cervical intraepithelial neoplasia (CIN) in women of reproductive age. In the past few decades, the management of CIN diagnosed during pregnancy has changed. Aggressive surgery has been replaced by a more conservative approach. The diagnostic and treatment guidelines have been revised and updated. Studies by several authors indicate that the course of CIN during pregnancy may vary. Regression of the lesions has been described in 10%–70% of patients. In our case, we will describe the approach to cervical intraepithelial neoplasia detected during delivery of a Syrian refugee patient with an unfollowed pregnancy.

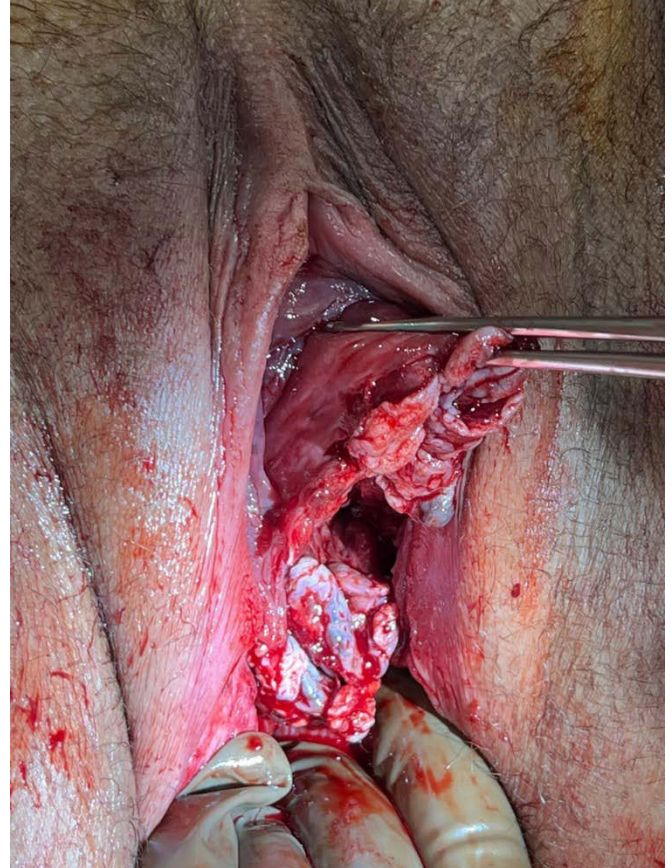
CASE: A 22-year-old (G2A1P0) Syrian refugee patient at 41 weeks of gestation without prenatal follow-up. Her medical history was unremarkable. Prenatal screening tests were not performed. She was a patient who applied to the emergency department with the complaint of pain. In the ultrasonographic evaluation, the patient's biophysical profile was normal and the estimated fetal weight was reported as 2800 grams. Cervical dilatation was evaluated as 6 cm and effacement as 50%. The patient who followed NST reagent during the follow-ups in the delivery room was delivered. A single live female baby with a 9/10 APGAR score, measuring 2920 grams/49 cm, was delivered by spontaneous vaginal delivery and right mediolateral episiotomy. In the cervical examination performed after the spontaneous separation of the placenta and its appendages, white patches of raised lesions were observed. (Figure 1) Pathological sampling was done from the lesion. No bleeding was observed in the lesion area. No pathological finding was found in the examination performed at the 2nd hour after birth. Blood test values were normal. In vaginal and rectal examination, puerperal findings were normal. In postpartum TA-USG, the endometrium was thin and regular, no free fluid was observed. The patient was discharged at the 28th hour of delivery, in good general condition, with stable vital signs, and without active vaginal bleeding. In the control of the patient on the postpartum 10th

day, regression was observed in the raised of the lesion. The patient's pathology report was reported as Low-grade squamous intraepithelial neoplasia (LSIL - CIN1). The patient was followed up by Gynecological Oncology.

DISCUSSION: Abnormal cytology is found in approximately 5%–8% of pregnant women while the prevalence of CIN in pregnancy is estimated at approximately 1% of the pregnant population. A Pap smear should be mandatory in pregnancy, preferably as a part of the first prenatal visit. This will allow detecting CIN during pregnancy, especially in case of women who have never had this test before. Although in many cases CIN tends to regress spontaneously after delivery, such outcome is not to be expected in all patients. Due to this condition, which we detected in our patient without follow-up, we recommend patients to have cervical examinations in their routine gynecological examinations, if not done before, at the first visit of pregnancy and in the postpartum period if necessary, and to have Pap - Smear test scans.

Keywords: Cervical intraepithelial neoplasia (CIN), Human papilloma virus (HPV), Pregnancy

Figure 1. Postpartum Cervical Examination image



SS-24

Response Rate of Secondary Line Chemotherapy in Patients with Relapsed Low Grade Serous Ovarian Cancer

Mehmet Efe Namlı, Esra Kuşçu, Huseyin Akilli, Mehmet Ali Abasıyanık, Atacan timuçin Kara, Dide Aysun, Rahma Eno Hassano, Tugba Tekelioglu, Ali Ayhan
Department of Gynecology and Obstetrics, Baskent University, Ankara, Turkey

AIM: The aim of this study was to investigate the effects of survival after the addition of bevacizumab to the second line chemotherapy regimen after recurrence in patients with low grade serous ovarian cancer.

MATERIAL-METHODS: In this retrospective and single-center study, a total of 29 patients who were diagnosed with relapsed low-grade serous ovarian cancer were included between January 2010 and May 2023. Clinicopathological characteristics of the patients, chemotherapy regimens were retrospectively documented.

RESULTS: In total, 29 patients were studied. Median follow-up time was 51 months (9-151). 19 patients (65.5%) were platinum sensitive and 10 patients (34.5%) were platinum resistant. Median PFS was found 10 months after second line chemotherapy. 12-24 months response rates were 41% and 10%, respectively. 16 (59.3%) patients received bevacizumab in addition to classical chemotherapy. 12 months response rate were 43% vs 18 % in patients who received or did not receive bevacizumab in addition to secondline chemotherapy, respectively ($p=0.02$)

CONCLUSION: In this retrospective study we found that the addition of bevacizumab to second line chemotherapy enhanced response but the results are unsatisfactory, so new chemotherapy agents are needed for low grade serous ovarian cancer.

Keywords: low grade serous, second line chemotherapy, bevacizumab

TABLO

Total Number of Patients	29
Median Age	40 (20-76)
Median Follow Up Time (months)	43 (9-151)
Median First Removed Tumoral Size(mm)	65 (16-190)
Median Total Lymph Node Removed	37 (4-62)
FIGO Stage	
1	1 (%3.4)
2	2 (%6.9)
3	22 (%75.9)
4	4 (%13.8)
Platin Sensitivity	
Sensitive	19 (%65.5)
Resistant	10 (%34.5)
Median Platin Free Interval (months)	8 (2-49)
Reccurence Site	
Local	15 (%51.8)
Distant	10 (%34.5)
Common	4 (%13.7)
Second Line Chemotherapy	
Paclitaxel + Carboplatin	3 (%10.3)
Paclitaxel + Carboplatin + Bevacizumab	9 (%31)
Lipozomal Doksorubicin	5 (%17.2)
Lipozomal Doksorubicin + Bevacizumab	7 (%24.1)
Letrozol	3 (%10.3)
Chemotherapy Regimen With Bevacizumab	
With	16 (%59.3)
Without	11 (%40.7)



5. Jinekoloji ve Obstetrikte Tartışmalı Konular Kongresi

5-8 Ekim 2023 | Hilton Dalaman Sarıgerme

SS-25

Results of rare brain metastases in ovarian cancer at a single tertiary hospital

Onur Atakul¹, Nejat Ozgul², Murat Gultekin², Hasan Volkan Ege², Bilal Esat Temiz¹, Derman Basaran²

¹Department of Obstetrics and Gynaecology, Hacettepe University, Ankara, Turkey

²Department of Obstetrics and Gynaecology, Division of Gynaecologic Oncology, Hacettepe University, Ankara, Turkey

Ovarian cancer is the seventh most common cancer in women, with approximately 314,000 new cases annually. The disease is usually asymptomatic in its early stages, and most patients are diagnosed at an advanced stage. The primary treatment for the disease involves a combination of cytoreductive surgery with chemotherapy or immunotherapy. Ovarian cancer mostly metastasizes within the peritoneal cavity. In stage 4 ovarian cancer, distant metastases are most commonly found in the liver. Brain metastasis (BM) is rare, with an incidence rate ranging from 1% to 2%). BM is considered a poor prognostic factor and is associated with reduced survival. However, due to the limited number of cases, there is no widely accepted guideline for the treatment. Management options for ovarian cancer patients with BM include radiotherapy, stereotactic radiosurgery, chemotherapy, and surgical treatment. In our study, we shared our experiences with patients who had tertiary single-center brain metastases from ovarian cancer.

Method: Data from patients diagnosed between January 2012 and June 2023 at Hacettepe University Hospital were collected retrospectively. Patients diagnosed with BM either radiologically or pathologically were included.

Results: The median age of the 10 included patients was 57 (min: 40, max: 77). Two patients presented with generalized tonic-clonic seizures, meanwhile the most common complaint was headache. During follow-up, BM was detected in 8 patients (recurrence), and BM was diagnosed at the initial presentation in 2 patients. The median time to BM occurrence was calculated as 31.4 months. At the time of BM diagnosis, the median CA-125 value for patients was 199 IU/ml (min: 4.6, max: 1584), with only one patient having a CA-125 value within the normal range. Most patients received combination treatment methods. Palliative supportive treatment was given to 3 patients. Radiotherapy (with or without chemotherapy) was administered to 7 patients, while surgery for BM was performed in 2 patients. The overall median survival after BM diagnosis was calculated as 7.1 months.

Conclusion: BM is rare in ovarian cancer patients. Due to the limited number of cases, there is no clear consensus on the ideal treatment approach. Even though treatment plans were tailored to individual cases, most of our patients had a general survival of less than one year. More studies with a larger number of patients are needed to determine the ideal treatment methods and to uncover differences in survival between treatments.

Keywords: Brain metastasis, Ovarian cancer, Stereotactic radiosurgery

SS-27

Largest single center data for endometrial intraepithelial neoplasia in Turkey

Hasan Volkan Ege¹, Nejat Ozgul¹, Murat Gultekin¹, Alp Usubutun³, Deniz Ates³, Bilal Esat Temiz², Derman Basaran¹

¹Department of Obstetrics and Gynaecology, Division of Gynaecologic Oncology, Hacettepe University, Ankara, Turkey

²Department of Obstetrics and Gynaecology, Hacettepe University, Ankara, Turkey

³Department of Pathology, Hacettepe University, Ankara, Turkey

Endometrial cancer (EC) is the most common gynecological malignancy in developed countries. The most prevalent subtype of the disease is endometrioid-type adenocarcinoma. This histological subtype develops from pre-cancerous lesions known as atypical endometrial hyperplasia or Endometrial Intraepithelial Neoplasia (EIN). Some risks have been identified between the diagnosis of EIN and EC. The risk of developing EC is accepted to increase by 45 times in cases diagnosed with EIN. Apart from the progression rate of the disease to cancer, the occurrence of cancer alongside EIN is possible. Simultaneous endometrial carcinoma can be detected in 15-40% of EIN patients. In our study, we shared our experiences related to patients diagnosed with EIN at our center.

Method: The study included patients diagnosed with EIN at Hacettepe University Hospital between January 2011 and March 2023. Demographic, clinical, and histopathological information of the patients were retrospectively reviewed at our center. All endometrial biopsy results were reported initially or reviewed by an expert co-author gynecopathologist. EIN diagnosis was established using subjective criteria.



5. Jinekoloji ve Obstetrikte Tartışmalı Konular Kongresi

5-8 Ekim 2023 | Hilton Dalaman Sarıgerme

Intraoperative pathological examination (Frozen) was performed according to the surgeon's discretion. Frozen examination was conducted by general pathologists. Mayo Clinic criteria were used for staging surgery if intraoperative pathology reveals EC.

Results: EIN diagnosis was established in 413 patients at our center, and 354 of these patients underwent surgery. The median age of operated patients was 49 (min: 31, max: 86), while the median BMI of the 289 patients with available data was 29.5. The majority of surgeries were performed as laparotomy (89.8%), while the remaining patients underwent laparoscopic or vaginal procedures. Hysterectomy, along with bilateral salpingo-oophorectomy was performed in 92.6% of the patients. In the final pathology reports, EC was detected in 11.3% (n: 40) of the patients. The majority of cancer cases were in Stage 1A (87.5%), while 10% of patients were in Stage 1B, and only one patient was in Stage 2. An intraoperative frozen study was conducted in 263 of the operated patients. In 7.6% of patients, discrepancies (more severe disease) were found between frozen results and final pathology. The sensitivity of intraoperative frozen study for EC detection was 41%, specificity was 100%, PPV was 100%, and NPV was 91.9%.

Conclusion: The best of our knowledge, this is the largest cohort of patients with EIN reported by a single center in Turkey. In our series, the incidence of EC in the final paraffin section report for patients with an initial diagnosis of EIN was 11.3%. This cancer rate is on the lower side of the previously reported incidence rates in the literature. We believe that our findings are associated with a formal gynecopathology review of endometrial biopsies prior to surgery, which can distinguish between cancer and other benign endometrial pathologies. In addition, we demonstrated that the proportion of EC cases requiring surgical staging is extremely low, and that intraoperative frozen section of EIN cases may be unnecessary if a gynecopathologist reports the initial EIN biopsy.

Keywords: EIN, Endometrial cancer, Endometrial intraepithelial neoplasia, Gynecopathology

SS-28

A practical approach for patient preparation prior to surgery in minimal invasive surgery

Hasan Volkan Ege¹, Nejat Ozgul¹, Murat Gultekin¹, Bilal Emre Erzenoğlu², Betül Güngör², Derman Basaran¹

¹Department of Obstetrics and Gynaecology, Division of Gynaecologic Oncology, Hacettepe University, Ankara, Turkey

²Department of Obstetrics and Gynaecology, Hacettepe University, Ankara, Turkey

The importance of laparoscopy in gynecologic surgery is increasing day by day. The frequency of minimal invasive approaches and consequently laparoscopy is progressively rising in gynecological operations.

As part of assistant training, many centers utilize training boxes or virtual reality applications alongside theoretical training for laparoscopy education.

Although these trainings are necessary to possess sufficient surgical skills before applying them on patients, it is essential to provide training to assistants for the arrangement of the operation room and the steps of preparing the patient for surgery.

On average, 10 new assistants join our center every year. To ensure that our assistants, who receive both theoretical and practical training through training boxes in line with the goal of mastering minimal invasive techniques in assistant training, can sufficiently prepare patients for surgery, we have developed sequential instructions (Figure-1) to facilitate and streamline the preparation process in the operating room. These instructions are placed in easily visible areas in all of our operating rooms to be reviewed before each laparoscopic surgery. The pre-operative preparation steps we apply in our center include;

- 1) Is the patient in the low lithotomy position?
- 2) Are the feet flat and thighs in a neutral position? (To protect the sacroiliac joint)
- 3) Is the lateral side of the knee protected? (To prevent peroneal nerve damage)
- 4) Are the arms in adduction and pronation? (To expand the range of motion and prevent brachial nerve damage)
- 5) Has bilateral shoulder support been placed? (To prevent the patient from sliding in deep Trendelenburg position)
- 6) Has the patient's buttocks been pulled down enough to the edge of the table? (To expand the manipulator's range of motion)

5. Jinekoloji ve Obstetrikte Tartışmalı Konular Kongresi

5-8 Ekim 2023 | Hilton Dalaman Sarıgerme

- 7) Has an orogastric tube been inserted?
- 8) Has a vaginal-bimanual examination been performed?
- 9) Has an appropriate uterine manipulator been chosen?
- 10) Has the patient been placed in deep Trendelenburg position and the sliding test been conducted?
- 11) Has the bladder been emptied with a Foley catheter or Nelaton catheter and the manipulator been correctly positioned?
- 12) Has the table been adjusted to a flat position before starting the surgery?

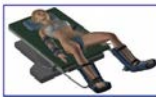CONCLUSION: By implementing these steps, we provide a standardized preparation, offering patients a safer chance for minimal invasive surgery, and aim to provide training assistants with a more practical approach to patient preparation.

Keywords: Assistant training, Laparoscopy, Minimal invasive surgery, Operating Room

Figure-1: Laparoscopic surgery preparation chart

JİNEKOLOJİK LAPAROSKOPİ HAZIRLIK AŞAMALARI

1) HASTA DÜŞÜK LİTOTOMİ POZİSYONUNDA MI ?	<input type="checkbox"/>	7) OROGASTRİK SONDA TAKILDI MI ?	<input type="checkbox"/>
2) AYAKLAR DÜZ VE UYLUK NÖTRAL POZİSYONDA MI ? (SAKROLYAK EKLEMİ KORUMAK İÇİN)	<input type="checkbox"/>	8) VAJİNAL-BİMANUEL MUAYENE YAPILDI MI ?	<input type="checkbox"/>
3) DİZİN LATERAL KORUNDU MU ? (PERONEAL SINIR HASARINI ÖNLEMEK İÇİN)	<input type="checkbox"/>	9) UYGUN UTERİN MANİPÜLÖR BELİRLENDİ Mİ ?	<input type="checkbox"/>
4) KOLLAR ADDUKSİYON VE PRONASYONDA SABİTLENDİ Mİ ? (HAREKET ALANINI GENİŞLETMEK VE BRAKİAL SINIR HASARINI ÖNLEMEK İÇİN)	<input type="checkbox"/>	10) HASTAYA DERİN TRENDLENBURG POZİSYONU VERİLİP KAYMA TESTİ YAPILDI MI ?	<input type="checkbox"/>
5) İKİ TARAFLI OMUZLUK YERLEŞTİRİLDİ Mİ ? (DERİN TRENDLENBURGDA HASTANIN KAYMASINI ENGELLEMELİK İÇİN)	<input type="checkbox"/>	11) MESANE FOLEY SONDA-NELATON SONDA İLE BOŞALTILIP MANİPÜLÖR DOĞRU ŞEKİLDE YERLEŞTİRİLDİ Mİ ?	<input type="checkbox"/>
6) HASTANIN KALÇASI MASANIN KENARINA GELECEK KADAR AŞAĞIYA ÇEKİLDİ Mİ ? (MANİPÜLÖRÜN HAREKET ALANINI GENİŞLETMEK İÇİN)	<input type="checkbox"/>	12) OPERASYONA BAŞLAMADAN ÖNCE MASA DÜZ POZİSYONA ALINDI MI ?	<input type="checkbox"/>



SS-29

Response Rate of Secondary Line Chemotherapy in Patients with Relapsed Low Grade Serous Ovarian Cancer

Mehmet Efe Namlı, Huseyin Akilli, Mehmet Ali Abasıyanık, Atacan timuçin Kara, Dide Aysun, Rahma Eno Hassano, Tugba Tekelioglu, Esra Kuşçu, Ali Ayhan
Department of Gynecology and Obstetrics, Baskent University, Ankara, Turkey

AIM: The aim of this study was to investigate the effects of survival after the addition of bevacizumab to the second line chemotherapy regimen after recurrence in patients with low grade serous ovarian cancer.

MATERIAL-METHODS: In this retrospective and single-center study, a total of 29 patients who were diagnosed with relapsed low-grade serous ovarian cancer were included between January 2010 and May 2023. Clinicopathological characteristics of the patients, chemotherapy regimens were retrospectively documented.

RESULTS: In total, 29 patients were studied. Median follow-up time was 51 months (9-151). 19 patients (65.5%) were platinum sensitive and 10 patients (34.5%) were platinum resistant. Median PFS was found 10 months after second line chemotherapy. 12-24 months response rates were 41% and 10%, respectively. 16 (59.3%) patients recieved bevacizumab in addition to classical chemotherapy. 12 months response rate were 43% vs 18 % in patients who recieved or did not recieve bevacizumab in addition to secondline chemotherapy, respectively (p=0.02).

CONCLUSION: In this retrospective study we found that the addition of bevacizumab to second line chemotherapy enhanced response but the results are unsatisfactory, so new chemotherapy agents are needed for low grade serous ovarian cancer.

Keywords: low grade serous, second line chemotherapy, bevacizumab

SS-30

High-Risk Oncogenic HPV Prevalence in Women with Vulvar Pruritus: A Prospective Comparative Study

Bilal Emre Erzeneoglu, Bilal Esat Temiz, Hasan Volkan Ege, Derman Basaran, Murat Gultekin, Nejat Ozgul
Hacettepe University

Vulvar pruritus, a distressing symptom, often prompts women to seek medical attention. This prospective study aimed to investigate whether a correlation exists between vulvar pruritus and the prevalence of high-risk oncogenic human papillomavirus (HPV) infection. The study was conducted at Hacettepe University Hospital from January to July 2023. Participants, aged 30 to 40 years, were randomly selected from the hospital's daily outpatient population. To ensure standardization and minimize confounding factors, single women with 1-4 lifelong sexual partners, no history of smoking, absence of additional diseases, and no condylomas were included.

METHODS: A total of 440 patients were enrolled, of which 429 had complete data available for analysis. The cohort was divided into two groups: the vulvar pruritus group (207 patients) and the control group (222 patients). HPV samples were collected and analyzed. The average age was 34.3 years in the pruritus group



5. Jinekoloji ve Obstetrikte Tartışmalı Konular Kongresi

5-8 Ekim 2023 | Hilton Dalaman Sarıgerme

and 35.1 years in the control group. The mean number of sexual partners until the sampling day was 2.6 and 2.4 for the pruritus and control groups, respectively.

RESULTS: In the vulvar pruritus group, 20.3% (42/207) of participants tested positive for high-risk oncogenic HPV, whereas in the control group, 17.1% (38/222) were HPV-positive. The odds ratio (OR) for high-risk oncogenic HPV infection among participants with vulvar pruritus compared to those without symptoms was calculated as approximately 1.429. The 95% confidence interval (CI) for the odds ratio was estimated to be (1.022, 2.007).

DISCUSSION: The calculated odds ratio of approximately 1.429 suggests that participants with vulvar pruritus were about 1.429 times more likely to test positive for high-risk oncogenic HPV infection compared to those without symptoms. The 95% confidence interval of (1.022, 2.007) indicates the range within which we are reasonably confident that the true odds ratio lies. The lower bound of the confidence interval was 1.022, while the upper bound was 2.007.

The study demonstrates a statistically significant association between vulvar pruritus and an elevated prevalence of high-risk oncogenic HPV. While high-risk oncogenic HPV infections do not predominantly manifest with pruritic symptoms, clinicians should exercise increased vigilance regarding cervical pathologies in asymptomatic patients. Further research is warranted to corroborate these findings and enhance our understanding of the relationship between vulvar pruritus and high-risk oncogenic HPV infection.

Keywords: Gynecological Oncology, HPV, Vulvar Disease, Vulvar Pruritus

SS-31

The role of office hysteroscopy in the diagnosis of symptomatic or asymptomatic patient groups in the premenopausal and postmenopausal periods

Betül Güngör¹, BİLAL ESAT TEMİZ¹, Bilal Emre Erzenoğlu¹, Hasan Volkan Ege², Derman Başaran², Nejat Özgül², Murat Gültekin²

¹Department of obstetrics and gynecology, Hacettepe University, Ankara, Turkey

²Department of gynecological oncology, Hacettepe University, Ankara, Turkey

Introduction: The role of office hysteroscopy in symptomatic or asymptomatic patients in the premenopausal and

postmenopausal period.

Material Methods: A retrospective evaluation of 544 patients who were evaluated by office hysteroscopy and then received endometrial biopsy in our hospital since 2017. Age, BMI, symptoms (asymptomatic vs. postmenopausal (abnormal uterine bleeding-AUK), tvUSG endometrial thickness, presence of focal lesion, histopathological tissue diagnoses were the parameters to be collected. We divided the patients into two groups as premenopausal (n=308) and postmenopausal (n=236). The remaining study group (n=544) were divided into 5 groups according to their histopathological diagnosis: benign/physiological endometrium (group A), endometrial polyp (group B), endometrial hyperplasia or intraepithelial neoplasia (EIN) (group C), endometrioid carcinoma (group D) and non-endometrioid carcinoma (group E).

Results: A total of 544 patients underwent office hysteroscopy and endometrial biopsy (132 asymptomatic, 412 abnormal uterine bleeding). The median age of the patients in the pre-menopausal group was 38.5, and the postmenopausal group was 58.1. The distribution of patients pre-menopausal group was n=171 (%55.7) Group A, n=113 (%36.8) Group B, n=12 (%3.9) Group C, n=10 (%3.2) Group D, n=1 (%0.4) Group E patients. The mean endometrial thickness is 9,6 mm, 10.5mm, 17.5mm, 19.5mm, 21,2mm, respectively. The distribution of patients postmenopausal group was n=151 (%64) Group A, n=63 (%26.7) Group B, n=7 (%3) Group C, n=11 (%4.7) Group D, n=4 (%1.6) Group E patients. Endometrial thickness was increasing from Group A to Group E. The mean endometrial thickness is 7.5mm, 10 mm, 11,4 mm, 12.1mm, 15.0mm, respectively. Cancer was detected in 20 (8.5%) patients in the postmenopausal period, and in 11 (3.5%) patients in the premenopausal group. Endometrial cancer was not present in patients who were asymptomatic in the postmenopausal and premenopausal periods. In the premenopausal period, endometrial cancer was detected in 3 out of 129 patients (%2.3) with focal lesions, while in the postmenopausal period, endometrial cancer was detected in 4 out of 109 patients (%3.6) with focal lesions. Among cases with focal lesions independent of menopausal status, endometrial cancer was identified in 7 out of 238 patients (%2.9).

CONCLUSION: The risk of endometrial cancer is observed more frequently as the measured endometrial thickness increases via ultrasound. However, in accordance with the current literature, it is seen more commonly in the postmenopausal period compared to the premenopausal period. The risk of endometrial cancer increases in patients with abnormal uterine bleeding regardless of age. In patients with focal lesions, complete removal of the lesion for histopathological evaluation, and in patients who cannot tolerate pelvic examination, careful pre-evaluation considering individual characteristics, office hysteroscopy can be recommended as an option due to its advantages in both diagnosis and treatment in appropriate indications.

Keywords: abnormal uterine bleeding, endometrial cancer, office hysteroscopy



5. Jinekoloji ve Obstetrikte Tartışmalı Konular Kongresi

5-8 Ekim 2023 | Hilton Dalaman Sarıgerme

SS-32

Effect of supplement containing Quercetin, Green Tea Extract, Licorice Extract, Cinnamon Extract, and Selenium on HPV clearance

Bilal Esat Temiz¹, Betül Güngör¹, Hasan Volkan Ege², Derman Başaran², Nejat Özgül², Murat Gültekin²

¹Department of obstetrics and gynecology, Hacettepe University, Ankara, Turkey

²Department of gynecological oncology, Hacettepe University, Ankara, Turkey

Introduction: Cervical cancer constitutes 3.6% of female cancers in developed countries and 15% in underdeveloped countries and is the fourth most common cancer. Almost all (99.7%) of the development of cervical cancer is associated with HPV. Although the studies in the literature show that the increase in vaginal microbiota diversity plays a role in the formation of persistent HPV infection, the number of studies evaluating the effect on women with preinvasive cervical epithelial lesions is still not sufficient. We observed evaluation of the effect of Papivir®, a supplement containing Quercetin, Green Tea Extract, Licorice Extract, Cinnamon Extract, and Selenium, on HPV infection and vaginal microbiota lesions.

STUDY DESIGN: In this retrospective study, we evaluated the records of 20 patients who were HPV positive and used supplemental oral capsule for HPV clearance (Papivir®), and 28 patients who did not receive vaginal microbiota treatment but applied for routine gynecological examination, who applied to the Hacettepe University Obstetrics and Gynecology outpatient clinic between January 2023 and June 2023. Papivir® was applied to patients during 3 + 3 months, after 6 months, it was controlled by HPV-DNA test. The counting data was analyzed via the chi-square test. All the p-values reported were two-sided, and p-values < 0.05 indicated statistical significance.

RESULTS: While the mean age of the papivir group was 33.1 years, it was 40.1 years in the control group. In the Papivir group, 10/20 (50%) HPV16, 2/20 (10%) HPV18, 6/20 (30%) other high-risk types, 2/20 (10%) low-risk as they will get HPV. HPV positivity persisted in 3/20 (15%) patients in the papivir group. In Papivir® group reported 17/20 (85%) HPV clearances at 6-month follow-up. In the control group, 6/28 (17.9%) HPV 16, 3/28 (10.7%) HPV 18, 13/28 (46.4%) other high-risk, and 6/28 (21.4%) HPV low -risk as HPV positive. Control group, negative HPV was detected in 11/28 (39.3%) patients at the end of 6 months. The 6-month follow-up of HPV in patients who received Papivir was 2.1-fold

higher compared with the control group.

Conclusions: While the incidence of industrialized cervical cancer has decreased in the last century, in some evolving fashion this rate of decline is much slower or even increasing. It is conceivable that Papivir® may be effective in clearing HPV infection in the near future and this innovative, non-invasive clinical intervention could be a new clinical approach and option for patients with persistent HPV infection and related diseases. There is a need for studies with more patients on the subject.

Keywords: HPV, VAGINAL FLORA, CIN

SS-33

The role of neutrophil/lymphocyte ratio as a predictor in diagnosis of ectopic pregnancy

Mustafa Deveci¹, Edis Kahraman¹, Güler Ateşer²

¹Acıbadem Atakent Hastanesi, Kadın Hastalıkları ve Doğum Kliniği, İstanbul, Turkey

²İstanbul Samatya Eğitim Araştırma Hastanesi, Kadın Hastalıkları ve Doğum Kliniği, İstanbul, Turkey

AIM: In this study we aimed to research the role of neutrophil/lymphocyte ratio as a predictor in the diagnosis of ectopic pregnancy.

MATERIALS-METHOD: The study has been done by screening and analysis of the data between dates of January 2006-January 2016 retrospectively. 145 ectopic pregnancy diagnosed patients without any co-diseases and the healthy routine controlled 140 first trimester pregnancies are included in the study. First visit hemogram values of healthy pregnancies and 2 hemogram values for each ectopic pregnancy patients which are the values at the diagnosis day and after treatment are screened and analysed. Demographic characteristics of patients and parameters of hemogram, especially neutrophil/lymphocyte ratio values are recorded and analysed.

RESULTS: When compared with the control group at the terms of age, gravida/parity; case group neutrophil/lymphocyte ratio values are found significantly higher (p<0,05). Furthermore, WBC and neutrophil number and ratio values are found significantly higher (p<0,05). Lymphocyte ratio at the case group is found as significantly lower (p<0,05). In addition, PLT, RDW, PDW and PLR values were similar between two groups. **Discussion and Results:** The success of the methods used for the diagnosis of ectopic pregnancies is lower than what it should be, and ectopic pregnancy is still one of the important reasons of maternal mortality.

In this study, we suggest that NLR values could be a helpful marker for the diagnosis of ectopic pregnancy.

Keywords: Ectopic pregnancy, haematological markers, neutrophil/ lymphocyte ratio, mean platelet volume.

SS-34

Management of recurrence of clear cell carcinoma involving the iliac arteries: An uncommon presentation

Murat Api¹, Sahra Sultan Kara², Esra Keles¹, Aslıhan Öztürk²

¹Department of GynecologicOncology,University of Health Sciences Turkey, Kartal Lütü Kirdar City Hospital, Istanbul 34668, Turkey

²Department of Obstetrics and Gynecology, University of Health SciencesTurkey, Kartal Lütü Kirdar City Hospital, Istanbul 34668, Turkey

INTRODUCTION: We presented a recurrent endometrial clear cell carcinoma with sites of recurrence restricted to the right inguinal region on the external iliac arteries were treated by resection of tumor and dissected in deep planes down to the pelvic floor with sacrificing the obturator nevre.

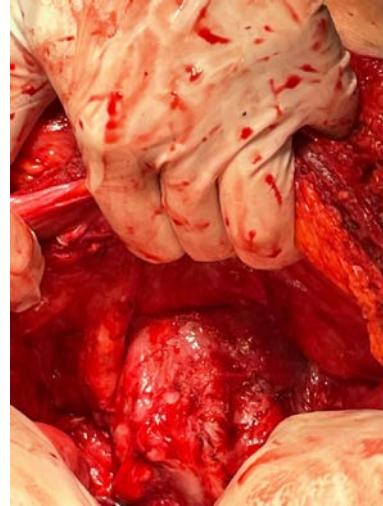
CASE: A 68-year-old female patient referred to our gynecologic and oncology department due to locoregional recurrence placed inguinal region with iliac arteries involvement. She had diagnosed with endometrial carsinoma and had been treated with total abdominal hysterectomy and bilaterally salphingo-oophorectomy in 2017. In addition, she had an history of recurrence and treated with inguinal lymphadenectomy in 2022 and received 6 cycles of adjuvant chemotherapy. In the ultrasound examination, an anechoic cystic mass measuring 68x34 mm and 44x51 mm was detected in the right parailiac area. MRI revealed that a multiloculated, septate, cystic lesion, approximately 8x5 cm in size on the right side, partially at the proximal level of the thigh, continuing at the level of the inguinal canal. Given the diagnosis, the patient was considered a candidate for surgery with curative intent. Through a midline laparotomy, we accessed the external and internal iliac arteries. A closely adhered tumor mass was observed, which affected more than 180° of the arterial surface (Figure 1,2). The external iliac artery and vein on the mass were completely dissected and released until the femoral artery bifurcation. Since the mass covered the symphysis pubis, obturator foramen musculus iliacus, and obturator muscles and involved the obturator nerve, the mass was excised together with the right obturator nerve. The R0 rate achieved with this

surgical procedure. The patient postoperative course was uneventful and was administered chemoteraphy.

DISCUSSION: There are few publications in the literature about the treatment of locoregional recurrences with involvement of large vessels. From the limited existing data, we can conclude that the involvement of large vessels in local recurrences should not be a contraindication for surgery with curative intent, as R0 resection is possible in selected patients.

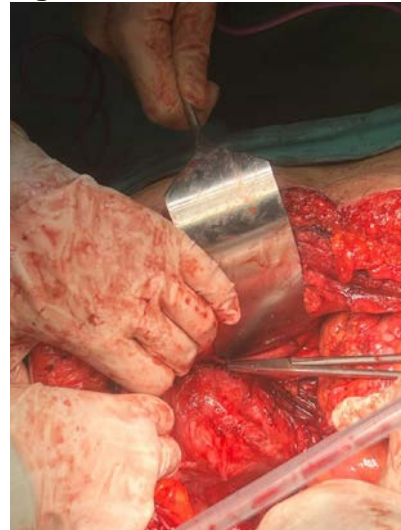Keywords: clear cell carcinoma, surgical resection, Endometrial cancer, Radical endometrial cancer surgery

Figure 1



A closely adhered tumor mass was observed, which affected more than 180° of the arterial surface

Figure 2



multiloculated, septate, cystic lesion, approximately 8x5 cm in size on the right side, partially at the proximal level of the thigh, continuing at the level of the inguinal canal.



5. Jinekoloji ve Obstetrikte Tartışmalı Konular Kongresi

5-8 Ekim 2023 | Hilton Dalaman Sarıgerme

SS-35

Lymph Node Involvement And Its Prognostic Impact In Ovarian Cancer Patients Who Received Neoadjuvant Chemotherapy

Dide Aysun, Huseyin Akilli, Tuğba Tekelioğlu, Mehmet Tunç, Mehmet Efe Namlı, Mehmet Ali Abasıyanık, Atacan Timuçin Kara, Rahma Eno Hassano, Esra Kuşçu, Ali Ayhan

Başkent Üniversitesi Ankara Hastanesi Kadın Hastalıkları ve Doğum Ana Bilim Dalı, Ankara

OBJECTIVE: This study aimed to evaluate the effect of lymph node metastasis on the prognosis of ovarian cancer patients who received neoadjuvant chemotherapy (NACT).

MATERIAL-METHODS: This retrospective single-center study was carried out at Baskent University, Ankara, Turkey. Patients with primary ovarian cancer who were diagnosed between 2007 and 2022 were evaluated. Patients' characteristics and tumoral features like age, CA 125, type of surgery, LN involvement, platinum sensitivity, and complete tumoral resection were retrospectively documented. Standard surgery was defined as total abdominal hysterectomy, bilateral salpingo-oophorectomy, infracolic omentectomy, bilateral pelvic and paraaortic lymphadenectomy, multiple peritoneal biopsies, and appendectomy. Any additional excision such as splenectomy, diaphragmatic resection, subtotal colectomy, etc. defined as extensive surgery.

RESULTS: A total of 173 patients were included. The median age was 58 (24-84). Median CA 125(IU/ml) level was 1191(17-20982). One hundred and fifty-one (87.3 %) patients had FIGO stage 3 disease at diagnosis and 18 (10.4%) had FIGO stage 4 disease. Seventy-two (%44.7) patients received 3 cycles of NACT and 89 (%55.3) had received more than 3 cycles. While 124 (%71.7) patients underwent standard surgery, 49 (28.3%) patients underwent extensive surgery. Lymph node metastasis was detected in 90 (52%) patients. Ninety (52%) of the patients were platinum-sensitive and 43.9 % (n:76) were platin resistant. Complete cytoreduction was performed on 91.3 % (n:158) of the patients and 6.4% (n:11) of the patients had incomplete surgery. Demographic and clinicopathological characteristics of the patients were given at table 1. Five-year overall survival (OS) rates were %20.1 and %23.4, median OS was 38 months (95% CI: 30.1-45.8) and 42 months (95% CI: 28.2-55.7) in patients with lymph node metastasis and without respectively (p:0.43). In univariate analysis, lymph node metastasis did not affect disease-free survival and OS (p:0.77). In multivariate analysis platinum resistance (HR:1.69, 95.0% CI: 1.14-2.50; p=0.008), and incomplete

resection (HR:3.64, 95.0% CI: 1.73-7.69; p=0.001) were associated with poor OS rate.

CONCLUSION: Lymph node involvement was not found as a prognostic factor for survival, in our retrospective study. Systematic lymphadenectomy might not be necessary for patients with advanced-stage ovarian cancer who received neoadjuvant chemotherapy.

Keywords: neoadjuvant chemotherapy, Lymph Node, prognosis

Table 1. Demographic and Clinicopathological Characteristics of the Patients

N:173	N (Range)
Median Age	58 (24-84)
Median CA 125(IU/mL)	1191 (17-20982)
Median preop alb (g/dL)	3.9 (2.41-4.80)
	N (%)
Surgery Type Standart Extensive	124 (71.7) 49 (28.3)
FIGO Stage 3 4	151 (87.3) 18 (10.4)
Gross tumor Negative Positive	47 (27.2) 123 (71.1)
Complete Cytoreduction No Yes	11 (6.4) 158 (91.3)
Histology High Grade Serous Low Grade Serous Clear Mucinous Endometrioid	149 (86.2) 11 (6.4) 4 (2.3) 2 (1.2) 2 (1.2)
LN involvement No Yes	68 (39.3) 90 (52.0)
Number of Neoadjuvant Chemotherapy Cycles 3 >3	72 (44.7) 89 (55.3)
Platinum Sensitivity Sensitive Resistant	90 (52.0) 76 (43.9)



5. Jinekoloji ve Obstetrikte Tartışmalı Konular Kongresi

5-8 Ekim 2023 | Hilton Dalaman Sarıgerme

SS-36

Adenomatoid tumor: A case report

Duygu Lafcı¹, Gülay Turan², Kübra Bil¹, Çağla Bahar Bülbul³, Ceyda Sancaklı Usta¹

¹Department of Gynecology and Obstetrics, Balıkesir University, Balıkesir, Turkey

²Department of Pathology, Balıkesir University, Balıkesir, Turkey

³Department of Gynecology and Obstetrics, Balıkesir City Hospital, Balıkesir, Turkey

Adenomatoid tumors, which are rarely seen in the female and male genital system, are benign. In the gynecologic system, they are most commonly seen in the uterus and fallopian tubes. These tumors, which radiologically resemble leiomyomas, are difficult to recognize preoperatively and are therefore often diagnosed by histopathologic examination of hysterectomy and/or salpingoopherectomy materials. Although adenomatoid tumors show typical features in terms of soft cytomorphology and histology, they can also be confused with lymphangioma and adenocarcinoma. In this case report, we present an incidentally diagnosed case of adenomatoid tumor of the fallopian tube with typical nuclear features.

A 52-year-old woman had an adenomyotic uterus with a submucous myoma of approximately 4 cm on the anterior uterine wall. No adnexal mass was found. She refused medical treatment and underwent laparoscopic hysterectomy and bilateral salpingoopherectomy (TLH-BSO).

Pathological examination revealed an adenomatoid tumor with a tumor diameter of 0.3x0.2 cm in the right tuba and the patient was followed up.

Adenomatoid tumors are rare tumors of mesothelial origin. They are benign.

Immunohistochemical staining plays an important role for the definitive diagnosis of adenomatoid tumors which can be confused with leiomyoma macroscopically, lymphangioma and adecarcinoma histologically. The treatment is surgical removal.

Keywords: Adenomatous tumor, Fallopian tube, Leiomyom

SS-37

Clinicopathological Discrepancies Between Expansile and Infiltrative Mucinous Ovarian Carcinoma

Mehmet Ali Abasıyanık¹, Huseyin Akilli¹, Mehmet Tunç¹, TUĞBA TEKELİOĞLU¹, Mehmet Efe NAMLI¹, Dide Aysun¹, Rahma Eno Hassano¹, Atacan Timuçin Kara¹, ASUMAN NİHAN HABERAL REYHAN², Esra Kuşçu¹, Ali Ayhan¹

¹Başkent Üniversitesi Ankara Hastanesi Kadın Hastalıkları ve Doğum Ana Bilim Dalı, Ankara

²Başkent Üniversitesi Ankara Hastanesi Patoloji Ana Bilim Dalı, Ankara

OBJECTIVE: We aimed to compare the clinicopathologic factors and oncologic outcomes of expansile and infiltrative types of primary mucinous ovarian carcinoma.

MATERIAL-METHODS: This study was performed at Baskent University, Ankara, Turkey. Patients who were surgically treated and finally diagnosed with primary mucinous ovarian carcinoma between 2009 and 2023 were evaluated, retrospectively. Clinicopathologic factors such as age, median tumor size, lymph node involvement, FIGO stage, and oncological outcomes including recurrence and overall survival rates were documented.

RESULTS: There were 28(53.8%) patients in the expansile group and 24 (46.2%) patients in the infiltrative group. Median patient age, tumor size, CA-125, and CA 19-9 were similar in between expansile and infiltrative groups; 44.5 vs. 46.0 years (p:0.95), 17.0 vs. 15.5 cm (p:0.88), 41.9 vs. 75.0 IU/ml (p:0.27) and 117.6 vs. 113.9 IU/ml (p:0.38), respectively. Twenty-six (50%) of expansile patients and 14 (26.9%) of infiltrative patients were diagnosed as FIGO early stage (1-2) (p:0.002). The infiltrative group had a longer hospital stay, 7 vs. 10.5 days (p:0.03). Adjuvant therapy was noted as 11 (21.1%) vs. 17 (32.6%) (p:0.02). Median follow-up time was longer in the expansile group 89.5 vs. 26.0 months (p:0.003). Five-year progression-free survival (PFS) rate and overall survival (OS) rate of expansile and infiltrative groups were 90% vs. 50% (p:0.001), and 92% vs. 31%, respectively (p:0.000). The infiltrative group and advanced FIGO stage were associated with diminished overall survival rate in multivariate analysis (HR:3.94; 95.0% CI: 1.13-13.80; p:0.03, and HR: 0.18; 95.0% CI: 0.06-0.56; p:0.003). Moreover, only the advanced stage was associated with a decreased PFS rate (HR:0.11, 95.0% CI: 0.02-0.47; p:0,003).

CONCLUSION: The infiltrative histological subtype of mucinous ovarian carcinoma was associated with higher lymph node involvement and recurrence rate in our study. Furthermore, it was found as an independent



5. Jinekoloji ve Obstetrikte Tartışmalı Konular Kongresi

5-8 Ekim 2023 | Hilton Dalaman Sarıgerme

poor prognostic factor for OS.

Keywords: mucinous carcinoma, primary mucinous ovarian carcinoma, infiltrative, expansile, overall survival, progression free survival

SS-38

Prognostic Factors in Stage IIIC2 Cervical Cancer Patients with Paraaortic Lymph Node Involvement

Rahma Eno Hassano, Huseyin Akıllı, Mehmet Tunç, Tuğba Tekelioğlu, Mehmet Efe Namılı, Mehmet Ali Abasıyanık, Atacan Timuçin Kara, Dide Aysun, Esra Kuşçu, Ali Ayhan
Başkent Üniversitesi Ankara Hastanesi Kadın Hastalıkları ve Doğum Ana Bilim Dalı, Ankara

AIM: The aim of this study was to investigate the prognostic risk factors in cervical cancer patients with paraaortic lymph node involvement.

MATERIAL-METHODS: Patients who were surgically treated and diagnosed finally with stage IIIC2 (positive paraaortic lymph node) cervical cancer between January 2010 and May 2023 were included. Clinicopathological characteristics of the patients and administered adjuvant therapies were retrospectively documented. Parametrial invasion, tumor size, histologic type, stromal invasion, and vaginal surgical margin were compared as possible prognostic factors.

RESULTS: A total of 50 patients were included in this study. The median age was 49.0 (31-75). The median follow-up time was 34.0 months. The median overall survival (OS) of the whole cohort was 34.5 months (3-137). Histologic subtypes were classified as squamous cell carcinoma (n:35, 70%), adenocarcinoma (n:5,10%), and adenosquamous carcinoma (n:10 20%) respectively. Of 50 patients, 12 (24%) received chemotherapy only as adjuvant therapy; while 38 (76%) underwent chemoradiotherapy. Twenty-seven patients (54%) had parametrial invasion. Demographic and clinicopathological characteristics of patients were given at table 1. Five-year OS in patients with and without parametrial invasion were 73.0% and 54.0%, respectively. Five-year disease-free survival in patients with and without parametrial invasion were 31.0% and 62.0%, respectively (p:0.04). Parametrial invasion was found as a negative prognostic factor for OS, and DFS [(HR: 3.7; 95% CI: 1.30-10.30, p:0.01, and HR:5.8; 95% CI: 2.04-16.92, p:0.001), respectively].

CONCLUSION: Parametrial invasion was found as an independent prognostic factor for patients with stage IIIC2 cervical cancer.

Keywords: cervical cancer, prognostic factors, parametrial invasion

SS-39

Aggressive angiomyxoma: A case report of cervical polyp

Duygu Lafcı¹, Gülay Turan², Kübra Bil¹, Çağla Bahar Bülbül³, Ceyda Sancaklı Usta¹

¹Department of Gynecology and Obstetrics, Balıkesir University, Balıkesir, Turkey

²Department of Pathology, Balıkesir University, Balıkesir, Turkey

³Department of Gynecology and Obstetrics, Balıkesir City Hospital, Balıkesir, Turkey

Aggressive angiomyxomas (AAM) are rare, benign mesenchymal tumors that occur especially during the reproductive period. This tumor is approximately 6 times more common in women than in men and is commonly located in the vulvovaginal region, perineum and pelvis. AAMs tend to show local infiltration, local growth and very rarely distant metastasis.

The term aggressive is emphasized due to its infiltrative nature and frequent association with local recurrence.

This tumor was first described by Steeper and Rosai in 1983, who described nine cases of benign-appearing fibro-myxoid tumors, each of which was locally aggressive but did not metastasize.

On histologic examination, they show a hypocellular and highly vascular cytology with a myxoid stroma containing soft stellate or spindle cells. Characteristically, estrogen and progesterone receptors are positive. Although this suggests that treatment with gonadotropin-releasing hormone agonists would be beneficial, surgical excision is the treatment of choice. However, because AAMs are rare and lack typical symptoms and signs, the diagnosis is often made histopathologically after surgery.

Macroscopically, AAM has an encapsulated appearance and is well circumscribed. The cross-sectional surface is flesh-colored and may contain cystic structures.

For this reason, it is frequently confused with a Bartholin cyst. On macroscopic examination, spindle-like stromal cells and vascular structures with large lumens are observed within a loose myxoid stroma.

Although treatment modalities such as hormonal manipulation, radiotherapy and arterial embolization have variable success rates, surgery is the first choice.

In this case report, we present a rare case of angiomyxoma with a rare localization in the cervix.

Keywords: angiomyxoma, cervix, cervical polyp



5. Jinekoloji ve Obstetrikte Tartışmalı Konular Kongresi

5-8 Ekim 2023 | Hilton Dalaman Sarıgerme

SS-40

Uterine Inversion: A case report

Kübra Bil¹, Duygu Lafcı¹, Çağla Bahar Bülbül², Kübra Ak¹, Ceyda Sancaklı Usta¹, Akın Usta¹

¹Department of Gynecology and Obstetrics, Balıkesir University, Balıkesir, Turkey

²Department of Gynecology and Obstetrics, Balıkesir City Hospital, Balıkesir, Turkey

Uterine inversion refers to the reversal of the fundus into the uterine cavity. Inversion carries a high risk of death due to bleeding and shock. The most common etiology of this very rare condition is umbilical cord traction. Other possible risk factors are often puerpal causes such as rapid labor, invasive placentation, manual removal of the placenta, short umbilical cord. Non-puerpal uterine inversion has been reported much more rarely in the literature and the most common cause has been described as submucosal leiomyomas.

The diagnosis of non-puerperal uterine inversion is made clinically, but nuclear magnetic resonance imaging and ultrasonography may be used if the clinical diagnosis is inadequate. If the uterine inversion is chronic, the patient mainly presents with irregular vaginal bleeding, signs of anemia and a feeling of a mass protruding from the vagina. In acute inversion, symptoms include pelvic pain and heavy vaginal bleeding. Acute inversion carries a risk of shock as it involves intense vaginal bleeding.

Some studies have reported that uterine inversion is associated with urinary events and extrinsic urethral compression.

Treatment depends on the patient's current clinical condition. Abdominal or vaginal hysterectomies should generally be considered in patients who do not want pregnancy, whereas in those who do want pregnancy, myomectomy should be preferred if possible. If malignancy as a non-puerpal cause cannot be ruled out, radical hysterectomy is recommended.

In this case report, we present a patient who was operated for uterine inversion.

Keywords: uterine inversione, hysterectomy, leiomyom

SS-41

Spinal anesthesia for cesarean delivery in a patient with cerebral venous sinus thrombosis: case report

Rezzan Berna Temoçin, Pınar Birol İter, Emre Mat University of Health Sciences Turkey, Kartal Lütfi Kırdar City Hospital, Department of Obstetrics and Gynecology, Istanbul, Turkey

Objectives: Venous sinus thromboses (VST) are venous blood clots of the major veins of the brain. Their symptoms will depend on the location and size of the clot. Venous sinus thrombosis occurs for similar reasons to other venous thrombosis. Anything that encourages clot formation, such as increased coagulation or decreased flow in a localized area of the sinus, predisposes to clot formation. Predisposing factors include hereditary coagulopathy, malignancy, oral contraceptive use, pregnancy, the postpartum period and spinal anesthesia, infection, trauma, or an underlying prothrombotic condition. Venous sinus thrombosis is rare, with current estimates that the incidence of venous sinus thrombosis ranges from 13.2 to approximately 15.7 per million patient years. Non-invasive and highly sensitive diagnostic methods such as magnetic resonance imaging (MRI), non-contrast cranial computed tomography (CT), and non-contrast two-dimensional time-of-flight (TOF) MRI venography and CT venography are used for diagnosis. There are several risk factors for CVT. Spinal anesthesia is also one of the rare risk factors. Diagnosis of the disease is difficult due to the diversity of clinical signs and symptoms. Headache is the most common reason for hospital admission. In this article, we aimed to present the importance of clinical evaluation of the cerebral vein thrombosis case that developed after cesarean section with spinal anesthesia.

Method: In this article, Kartal Dr. Evaluated at Lütfi Kırdar City Hospital Gynecology and Obstetrics Clinic; The data of a case of cerebral vein thrombosis that developed after cesarean section under spinal anesthesia was evaluated retrospectively.

Results: A cesarean section operation was performed under spinal anesthesia to a 29-year-old female patient who had no known disease and had no special features other than a previous cesarean section. On the second postoperative day, the patient's general condition was good and his vitals were within normal range, and discharge was planned. On the 3rd postoperative day, the patient was admitted to the emergency department with the complaint of severe throbbing headache, and the pain was evaluated as postdural headache and analgesic was administered. However, an MRI was planned for the patient, whose pain did not completely

disappear with analgesics and whose pain started to become more severe soon after. The patient, whose MRI detected a thrombus in the superior sagittal sinus, was started on heparin treatment with an infusion of 18 U/kg/hour. The patient's complaints resolved after the treatment and he was discharged with a warfarin prescription on the 13th day of his hospitalization. The patient was completely healthy at the outpatient clinic check 6 months later.

Discussion: Post-spinal anaesthesia CVT is seen at a rate of 0.1–0.5%, and it is generally related to underlying predisposing factors. For clinical problems with various neurologic complaints that developed in the postpartum period, especially in high-risk patients such as those who are pregnant and underwent the application of spinal anaesthesia, CVT should be a considerable cause, and it should be considered that delayed diagnosis and treatment can negatively affect prognosis.

Keywords: Cerebral vein thrombosis, cesarean, spinal anaesthesia

SS-42

Left sided suprapubic vertical rectus abdominis musculocutaneous flap after pelvic exenteration for recurrent vulvar cancer

Cansın Arzum Demirkıran Usta¹, Nejat Ozgul², Murat Gultekin², Gökhan Sert³, Derman Basaran²

¹Department of Obstetrics and Gynaecology, Hacettepe University, Ankara, Turkey

²Department of Obstetrics and Gynaecology, Division of Gynaecologic Oncology, Hacettepe University, Ankara, Turkey

³Department of Plastic Reconstructive and Aesthetic Surgery, Hacettepe University, Ankara, Turkey

The salvage procedure for recurrent vulvar cancer in previously irradiated patients is pelvic exenteration (PE). PE is related to significant morbidity and mortality that are associated with Empty Pelvis Syndrome (EPS). Here, we present a case of recurrent vulvar cancer in which the Vertical Rectus Abdominis Musculocutaneous (VRAM) flap was utilized to prevent EPS.

Case Presentation

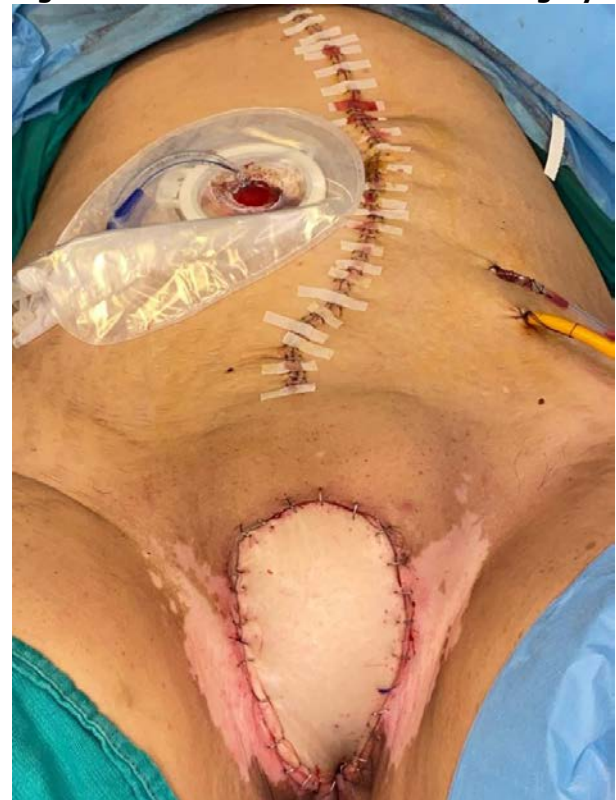A 58-year-old patient with a history of radical vulvectomy and bilateral inguofemoral lymph node dissection for lichen sclerosis associated vulvar cancer was referred to our clinic for recurrence 2 years after initial surgery. A localized central recurrent disease was identified under

the urethra and on the anterior vaginal wall. With no distant metastasis, anterior exenteration was decided upon. Urology and plastic surgery departments were included in the surgical treatment planning. Abdominal aorta and bilateral lower extremity computed tomography angiography were performed to determine the flap area. The patient underwent Anterior Exenteration, Pedicled left sided VRAM Flap Reconstruction, creation of an ileal loop, and uretero-ileal anastomosis using the Bricker technique. The VRAM flap was advanced through a subcutaneous tunnel in the perineum, passing over the pubic bone, and no circulation problems were observed (Figure 1) Abdominal side wall integrity was achieved with using a dual sided vicryl and prolene mesh. Post-operative course was uneventful except wound separation on the perineal margin of the flap which was followed with conservative approach. The patient was discharged on the 9th postoperative day. Pathological evaluation revealed no tumor at the surgical margins.

Conclusion: The musculocutaneous VRAM flap can be used in cases of anterior exenteration for both closing defects after tissue excision and preventing Empty Pelvis Syndrome. Flap can be placed over the pubic bone to prevent pedicle torsion.

Keywords: Empty pelvis syndrome, Pelvic exenteration, Vulvar cancer, VRAM flap

Figure-1: Vulva and abdomen after surgery



SS-43

Approach to a retroperitoneal neural origin pelvic mass.

Edis Kahraman, Aysel Nalçakan, M. Faruk Kose
Acıbadem Üniversitesi Atakent Hastanesi

AIM: Pelvic mass is common gynaecological problem, which can present with symptoms as abdominal pain, tenderness, menstrual disorders, infertility etc. Depending of origin of the mass, symptom and prognosis may vary. In this case, we aimed to present a rare pelvic mass, retroperitoneal neural origin tumor.

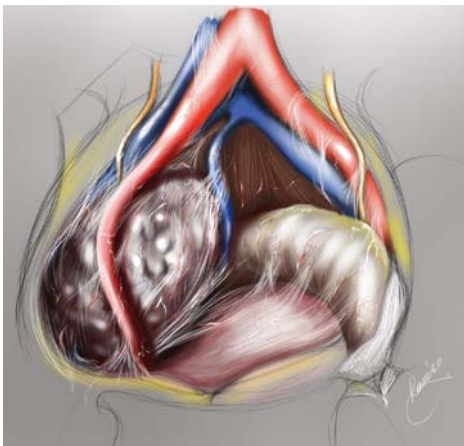
CASE: 49 years old women came to our clinic with abdominal pain, ultrasound examination showed 8cm heterogenous right pelvic mass which compresses uterus and bowels, causes constipation as well. Tumor markers are negative, we could not identify isolated right ovary so decided diagnostic laparotomy for right pelvic mass. In operation, we noticed the right ovary looks normal, the mass locates in retroperitoneal area, right border of mass was external iliac vessels, above the mass the ureter was adhered and dilated, medial border of the mass was lumbar vertebrae and its vessels and caudal border of the mass was obturator fossa. We dissected the mass without any complication and the final pathology was alveolar soft part sarcoma.

DISCUSSION: Imaging techniques such as MRI and USG are very useful to locate the masses or determine the nature of masses, but retroperitoneal masses are very difficult to locate, preoperatively.

In same rare cases, origin of pelvic masses are not ovaries or tuba, so a gynecological surgeon should be ready to explore and operate retroperitoneal area.

Keywords: soft part sarcoma, retroperitoneal mass, pelvic mass, neural origin pelvic mass.

Retroperitoneal pelvis mass



SS-44

Laparoscopic intraoperative ultrasound in adnexal mass

Edis Kahraman, Mustafa Deveci, Emine Karabuk, M. Faruk Kose
Acıbadem Üniversitesi Atakent Hastanesi

AIM: Laparoscopic ultrasound use is gaining popularity in last 3 decades. The laparoscopic surgeon can use many advantages of this instrument. The surgeon sees only the surface of the organs and can't palpate the anatomical structures. In this paper, we aimed to present a case in which we used laparoscopic ultrasound to locate nodular cyst of normal sized ovary with normal outside appearance.

MATERIAL METHOD: 38years old healthy woman came to our clinic for routine gynaecological exam without any symptom. During routine transvaginal ultrasound, we detected 3cm suspicious cyst with nodular structure in her right ovary. We planned diagnostic laparoscopy, cystectomy, or oophorectomy with frozen section. During surgery, laparoscopic ultrasound has been used to locate the cyst.

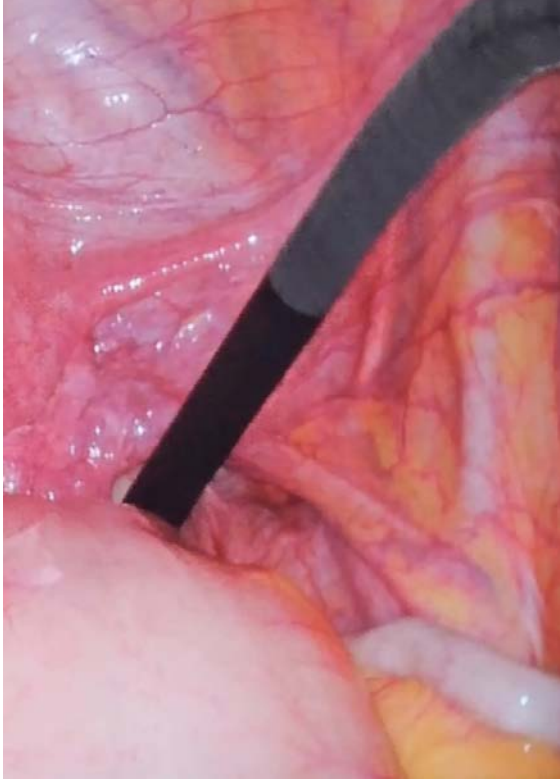RESULT: Laparoscopic ultrasound is very useful tool to locate deep small fibroids during myomectomy, to examine cystic structures of ovaries and very helpful to determine the nature of the masses. In our case, nodular cyst was highly suspicious, so we performed oophorectomy, which had diagnosed as borderline tumour pathologically.

DISCUSSION: As minimal invasive approach in surgery getting more popular, various tools to minimise misdiagnosis, over-treatment should be used, and surgeons should aim more and more accurate diagnosis and treatment. Laparoscopic intraoperative ultrasound use is highly popular in hepatobiliary surgent, which is very helpful examine and locate a mass in deep liver parenchyma. There are also many advantages of using intraoperative laparoscopic ultrasound in the fields of gynaecology.

CONCLUSION: Laparoscopic ultrasound can help gives the opportunity to see and locate anatomical structures of inner layers of organs.

Keywords: borderline, intraoperative ultrasound, laparoscopic ultrasound, minimal invasive

Laparoscopic intraoperative ultrasound probe.



of the cyst remained stable but an echogenic mass measuring 35x22 mm appeared inside the cyst. It was also observed that a second anechoic 27x25 mm cystic lesion was formed next to the other one. The patient had ultrasound evaluation and non-stress test weekly until delivery. At 38 weeks of gestation, the cyst increased to 71x53 mm but echogenic mass remained stable. At that time, fetal growth restriction was detected with an estimated fetal weight at 2 percentile. Doppler flow examination was normal. The patient was admitted to the hospital and an induction of labor was scheduled. A 2400-g baby girl was delivered with Apgar scores of 8 and 9 at 1 and 5 minutes, respectively. Postnatal examination of the baby was normal, and the neonatal course was uneventful. The placenta weighed 520 g, measured 18x11x7 cm, and had a three-vessel cord. A subchorionic cyst measuring 70x60 mm with a hematoma inside located near the insertion of the umbilical cord and another 30x20 cystic lesion were found.

Discussion: Most placental cysts are single and the pregnancy outcome is favorable. However, large and multiple cysts should be followed carefully as they may cause fetal growth restriction.

Keywords: fetal growth restriction, placental cyst, placental lesion, umbilical cord

SS-45

Subchorionic placental cysts as a cause of fetal growth restriction

Aslıhan Öztürk¹, Elif Gizem Dizdaroğulları², İsmail Bağlar¹

¹Department of Obstetrics and Gynecology, Kartal Dr. Lutfi Kırdar City Hospital, Istanbul, Turkey

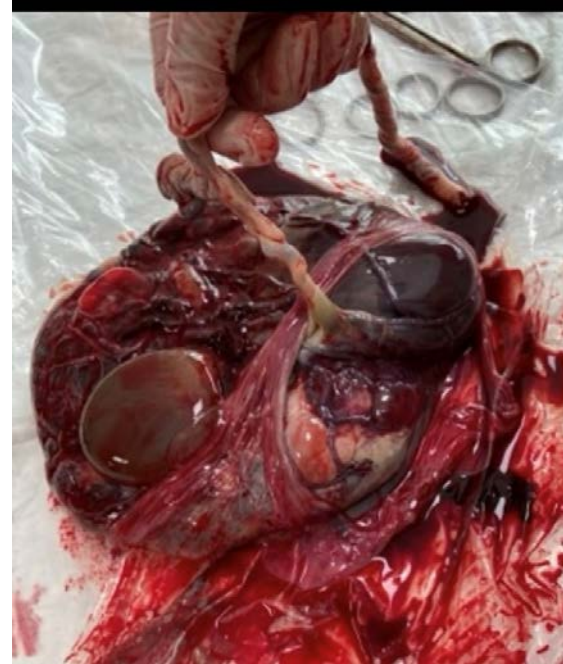²Department of Perinatology, Kartal Dr. Lutfi Kırdar City Hospital, Istanbul, Turkey

Introduction: Subchorionic placental cysts are frequent but there are contradicting opinions about their clinical importance. We describe a case with subchorionic cysts arising near the placental cord insertion site with intracystic hemorrhage, diagnosed by ultrasound and complicated by fetal growth restriction.

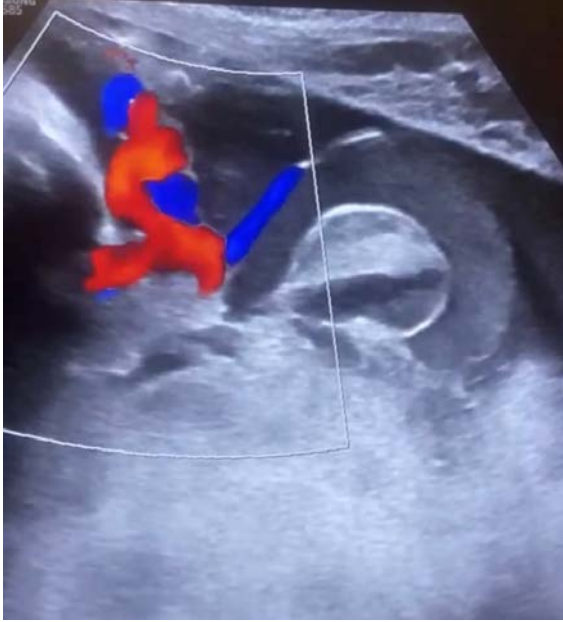Case Report

A 28-year-old primigravid woman presented at our hospital for a fetal anomaly scan at 24 weeks of gestation. Her medical history was unremarkable. Ultrasound examination was normal except for an anechoic cystic lesion measuring 15x25 mm near the insertion of the umbilical cord. At 29 weeks of gestation, the follow-up scan revealed that the cyst increased in size to 51x27 mm. At 30 weeks, the size

Postpartum examination of the placenta



Subchorionic cystic lesion with an echogenic mass



SS-46

A case of abdominal wall endometriosis after cesarean section

Elif Betül Esmer, Mustafa Ayhan Ekici, Pınar Fatma Kızılırmak, Ebru Kaynar
Department of Obstetrics and Gynecology, Abant İzzet Baysal University, Bolu, Turkey

INTRODUCTION:: Endometriosis is the abnormal location of endometrial glands and stroma on any part of the body apart from the endometrial cavity(1). The prevalence of subcutaneous abdominal wall endometriosis (AWE) after cesarean section is between 0.03% and 1%, and it constitutes 1% of all external endometriosis cases. AWE is usually found in the old incision scar line (2). In this case report, we aimed to present a patient who had 3 cesarean section (C/S) and presented with dysmenorrhea and was found to have an AWE 3cm above the scar line

CASE: A 31 year old patient, gravida 3, parity 3, with a history of three C/S and her last delivery was 3 years ago, applied to our clinic due to pain and palpable tender mass in the upper right corner of the C/S scar line that had been going on for about 8 months. The patient stated that the pain is increasing especially during menstrual periods. During physical examination, a hard, painful mass, approximately 3*4 cm in size, located subcutaneously, was palpated on the right side of the C/S scar line and 3 cm above the incision. In the superficial ultrasonographic evaluation, a heterogeneous

lesion, approximately 26x28x30mm in size, 7mm deep under the skin, and with blood supply on color Doppler ultrasonography, which could be compatible with endometriosis, was observed. The patient was taken into surgery. Under general anesthesia, a 2cm transverse incision was made on the right side, approximately 3cm above the C/S incision line. The mass was reached under the skin. It was observed that the mass had no connection with the fascia (Figure-1). The approximately 4cm mass was completely excised and sent for histopathological examination (Figure-2) The operation was ended following bleeding control and incision suturing. The patient was discharged uneventfully on the first postoperative day. Histopathological examination revealed that the mass was compatible with endometriosis.

DISCUSSION: Observing subcutaneous AWE after C/S is a rare pathology(3). It is thought to develop by the differentiation of endometrial stem cells that settle in or around the incision line after C/S (4). The most common symptoms are cyclic pain, tenderness and a palpable mass on the lesion during menstruation. Risk factors include previous gynecological surgeries related to the endometrial cavity. This situation is explained by iatrogenic implantation (5) Ultrasound, computed tomography (CT) and magnetic resonance (MRI) can be used in diagnosis. Usually, a hypoechoic solid mass appearance around the scar line is seen on ultrasonography, and the definitive diagnosis is made by histopathological examination. Surgical local excision is recommended for treatment(6). In order to prevent subcutaneous endometriosis after cesarean section, it is recommended to irrigate with physiological saline and change the gloves, needles, suture materials and sponges used before the procedure is terminated (7). As a result, subcutaneous endometriosis should be considered in the differential diagnosis, especially in women of reproductive age who have undergone pelvic surgery and have menstruation-related mass and cyclic pain. The first option in treatment is known as wide local excision.

Keywords: abdominal wall endometriosis, cesarean section, external endometriosis

figure-1

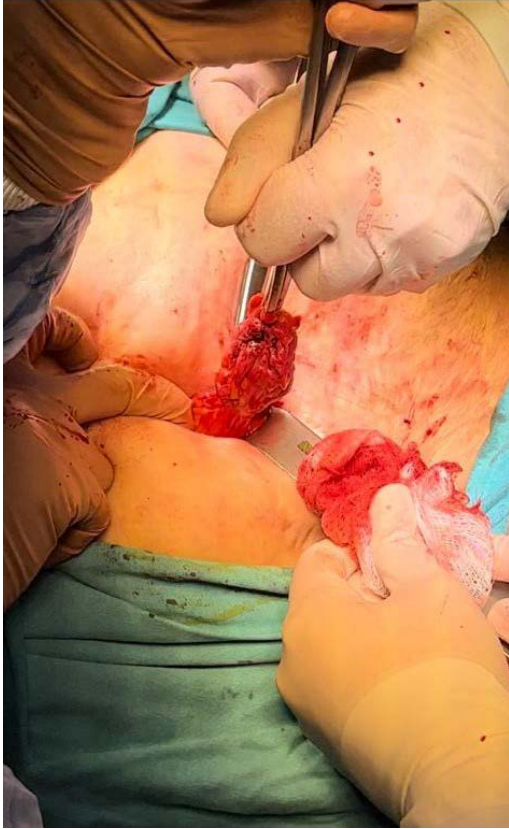
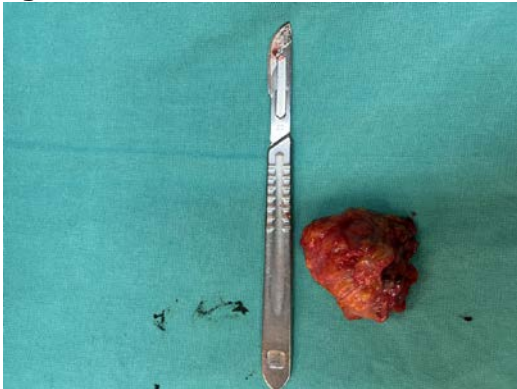
figure-2



SS-48

Effect of Maternal Distilled Water and Tap Water Hydration on Amniotic Fluid Index and Perinatal-Postnatal Outcomes in Third Trimester Pregnant Women Diagnosed with Isolated Oligohydramnios: a Randomized Controlled Study

Emine Yıldız Kesen Kugu, Burak Karadağ, And Yavuz, Ceyda Karadağ, Elif Ayan Avcı, Serap Fırtına Tuncer
Ministry of Health University Antalya Training and Research Hospital Department of Obstetrics and Gynecology

AIM: This study was aimed to compare effects of maternal oral tap water and distilled water hydration therapy on amniotic fluid volume (AVF) and perinatal-postnatal outcomes in third trimester pregnant women diagnosed with isolated oligohydramnios (IO).

MATERIALS-METHODS: A total of 40 participants diagnosed with IO were included in the study between February 2022 and June 2022. A total of 2000 ml distilled water was intaken daily for seven days by the first 20 participants (Group 1) and a total of 2000 ml tap water was intaken Daily for seven days by the last 20 participants (Group 2). Fetal biometric measurements of the participants were performed at the beginning of the study and at the end of the study by the same physician. Primary outcome was the effect of hydration on the amniotic fluid index (AFI) and secondary outcomes were perinatal outcomes.

RESULTS: There was no significant difference in terms of demographic characteristics, fetal biometric measurements, uterine artery Doppler index, gestational age at delivery, the rate of primary cesarean deliveries, birth weights and birth height, neonatal intensive care unit admission, laboratory outcomes between the groups ($p>0,05$). There was no significant difference in pre-hydration in AFI values between the groups [$55,80\pm12,14$ vs $57,15\pm10,97$; ($p=0,714$)], but a statistical significant difference was found in post-hydration in AFI values [$77,80\pm11,56$ vs $44,30\pm10,90$; ($p<0,001$)].

CONCLUSION: This study showed that maternal oral hydration is an easily applicable and effective methods in the treatment IO. Prospective studies with larger numbers of participants are needed to confirm to validate the findings of this study.

Keywords: distilled water, oligohydramnios, perinatal outcomes

SS-50

A case of a term pregnancy in a unicornuate uterus with non-communicating rudimentary horn

PINAR FATMA KIZILIRMAK, Ulku Mete Ural, Ebru Kaynar, Elif Betül Esmer
Department of Obstetrics and Gynecology, Bolu Abant İzzet Baysal University, Bolu, Turkey

INTRODUCTION: Unicornuate uterus, one of the Müllerian anomalies, as a rare malformation causes obstetric and gynecological problems in patients. Hysterosalpingography (HSG), laparoscopy, hysteroscopy and ultrasonography (USG) are primarily used in its diagnosis. Treatment is shaped according to reproductive expectations and complaints of the patient. Pregnancy in a unicornuate uterus is rare and when it occurs, it seldom progresses to term. In this case report, we aimed to present a pregnancy in an unicornuate uterus with non-communicating rudimentary horn which was reached term.

CASE: A 35-year-old pregnant woman with gravida 3, parity 2, who had her other deliveries by cesarean section, had a planned cesarean section on the 38th week and 6th day of her pregnancy. Intraoperative observation revealed a right unicornuate uterus with left non-communicating rudimentary horn (Figure 1). It was observed that the bilateral ovaries were normal and the left fallopian tube was absence. The patient's other two pregnancies also terminated after 38th gestational week. She did not have a history of infertility and did not experience any pregnancy complications like premature rupture of membranes and preterm delivery. The patient's postoperative course was uneventful and she is discharged on the second postoperative day. Informed consent was obtained from the patient for publication of this case report and accompanying images.

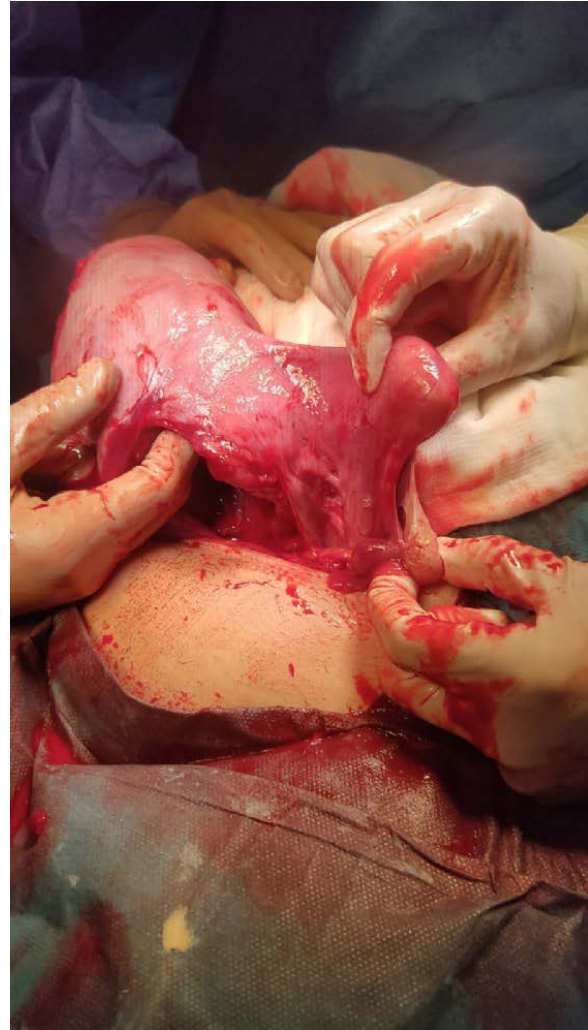DISCUSSION: Abnormal fusion of the müllerian duct or insufficiency of septum absorption in the early embryonic period results in anatomical malformation in the genital. According to the literature, the unicornuate uterus accounts for 2.4 % to 13 % of all Müllerian anomalies. The prevalence of a unicornuate uterus is 0.1 %. The presence of a unicornuate uterus is associated with adverse obstetric outcomes, including recurrent miscarriage, premature delivery, fetal malposition, intrauterine growth retardation, post-partum hemorrhage, and uterine rupture. In addition, around 40 % of women with this malformation may experience infertility. Endometriosis, hematometra and urinary tract anomalies are common. According to the literature, only 30 % of these pregnancies reach full term. As a rare case our patient had 3 term-pregnancies without any complication related to this anomaly.

Removal of the rudimentary uterine horn is now considered the preferred surgical approach for treating dysmenorrhea, ectopic pregnancy and retrograde menstruation in affected patients. The removal of asymptomatic rudimentary horns containing endometrium is recommended too. Although prophylactic cervical cerclage has not been fully established in improving obstetric outcomes, their usefulness is suggested by current medical practice.

Unicornuate uterus should be suspected with atypical ultrasonographic features and more investigations done to confirm the precise diagnosis in order to reduce the associated morbidity and mortality. This will enable timely obstetric management and prevention of complications.

Keywords: Rudimentary horn, term pregnancy, unicornuate uterus

Figure-1



SS-51

Comparison of serum neuropeptide y and nesfatin levels in infertile patients with the fertile patient group and their relationship with treatment results

Ayşenur Akkoç, İBRAHİM VEYSEL FENKÇİ, Cihan Kabukçu, Umit Cabus
Pamukkale University, Denizli, Turkey

OBJECTIVE: Neuropeptide Y (NPY) neurons found in the arcuate nucleus of the hypothalamus play a role in regulating metabolic homeostasis and energy balance. NPY neurons are crucial in metabolic disorders, including obesity, glucose tolerance, hypertension, and atherosclerosis. It is known that NPY plays a direct regulatory role on ovarian granulosa cells. It is known that NPY plays a direct regulatory role on ovarian granulosa cells. It has been reported that NPY induces the proliferation of preantral and early antral follicle granulosa cells, as well as the apoptosis of late antral follicles. Nesfatin is an adipokine that regulates energy metabolism and glucose homeostasis. It has been shown that nesfatin has a glucose-dependent insulinotropic effect and influences ovarian function. In our study, we aimed to investigate the relationship between NPY and nesfatin levels with metabolic and clinical parameters and their impact on treatment outcomes in patients undergoing IVF.

METHODS: Our study was conducted between November 2021 and January 2022 and included 30 patients who had IVF treatment at the Pamukkale University Faculty of Medicine IVF Center, along with 29 fertile women who had previously conceived spontaneously and had a history of healthy childbirth and who presented to the Gynecology outpatient clinic for benign reasons. In both groups, on the 2nd day of their menstrual cycle, peripheral venous blood samples were taken to measure the levels of neuropeptide Y and nesfatin. Additionally, the patients' body mass index (BMI), serum hormone levels and clinical data and outcomes related to IVF treatment were recorded.

RESULTS: The average age of the infertile patient group who underwent IVF was 31.6 ± 4.8 , while the average age of the control group was 34.3 ± 5.1 . The average BMI values were found to be 25.4 ± 5.9 in the infertile group and 27.0 ± 3.6 in the control group. There was no significant difference between the two groups. In the infertile group, the NPY level was measured as 84.4 ± 29.9 pg/ml; in the control group, it was 56.0 ± 37.9 pg/ml. The independent samples t-test revealed a significant difference between the two groups, $t(57)=3.19$, $p=0.002$. In the infertile group, the Nesfatin level was measured as 913.5 ± 1419.3 ng/ml; in the control group, it was 1876.2 ± 2494.6 ng/ml. Istatistically significant difference was not found between the two groups. $t(57)=1.83$ $p=0,073$. Among

the patients who underwent IVF, 12 (40%) tested positive for pregnancy, while 18 (60%) tested negative. When the levels of NPY and nesfatin were compared according to pregnancy outcome, no significant difference was observed between positive and negative patients. ($p=0,390$, $p=0,415$).

CONCLUSION: It has been reported in previous studies that NPY induces the proliferation of preantral and early antral follicle granulosa cells, as well as the apoptosis of late antral follicles. The statistically significant higher levels of NPY found in the infertile patient group compared to the control group in our study suggest that NPY may affect ovulatory functions and oocyte development. The number of studies in the literature investigating the relationship between NPY and infertility is insufficient. More studies can be conducted to examine the effect of NPY on ovarian function.

Keywords: infertility, neuropeptide Y, nesfatin, IVF, ovarian function

SS-52

Heterotopic Pregnancy: A Rare Case

Kübra Ak¹, Alperen Baykal², Esra Şimşekoğlu², Ceyda Sancaklı Usta², Akın Usta²

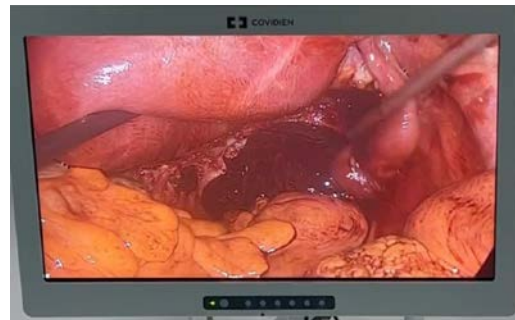
¹Department of Gynecology and Obstetric, Dursunbey State Hospital, Balıkesir, Turkey

²Department of Gynecology and Obstetric, Balıkesir University Health Practice and Research Hospital, Balıkesir, Turkey

Heterotopic pregnancy is common in assisted reproductive techniques but rarely seen in natural pregnancy. A high index of suspicion may aid early diagnosis and appropriate intervention. Here, we report a case of heterotopic pregnancy in a 28-year-old woman with a 7-week viable intrauterine pregnancy with hemoglobin drop due to ruptured tubal ectopic pregnancy and diagnosed on ultrasound examination with clinical follow-up.

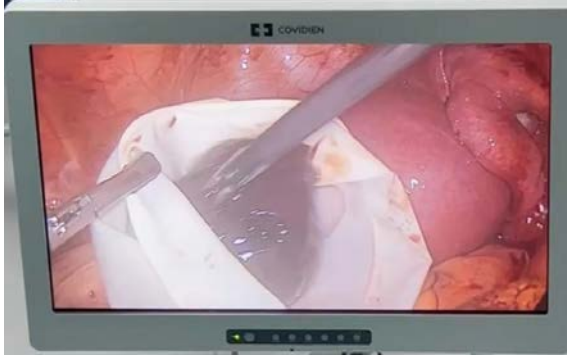
Keywords: natural cycle, heterotopic pregnancy, laparoscopy

1



sol tuba rüptürü

2



ektopik gebelik ürününün batin dışına çıkarılmak üzere kese içine alınması

SS-53

A rare case: clitoral schwannoma and review of literature

Kübra Sevinç, Fazıl Avcı, Sezer Seda Yılmaz, Özlem Seçilmiş, Zeliha Esin Çelik, Çetin Çelik
Selcuk University Medical Faculty Department of Obstetrics and Gynecology, Konya Turkey

AIM: Our aim in this case report is to present a 28-year-old patient diagnosed with clitoral schwannoma who applied to the clinic due to a clitoral mass.

MATERIAL-METHODS: We presented this rare case of clitoral schwannoma, its clinical findings and pathological results.

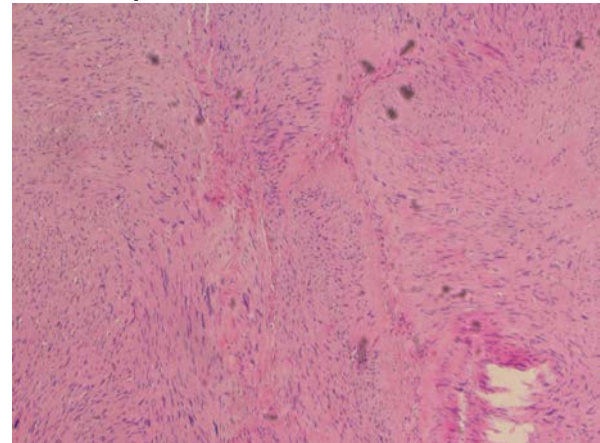
CASE: A 28-year old Turkish woman who had no children, presented with in September 2022 for examination of a painless and slowly growing mass in clitoris. She noticed 3 years before. At first it was small and not painful at all but it had gradually increased and began to affect daily activities because of mass's size. Physical examination revealed 2x2 cm in size, subcutaneous, moveable, nontender nodule with an irregular contour at the superior to the clitoris. It was not attached to the skin or underlying tissues. There was no lymphadenopathy. No evidence of neurofibromatosis or virilism was found. Other than this lesion, the patient's external genitalia were completely normal. There was no remarkable past medical, social or familial history of cancer or hereditary genetic disease. After simple excision of the tumor with a clear margin, histopathology report showed that the resected specimen was an soft, encapsulated, well-circumscribed lesion. It had pale yellow lobular and focally multinodular cut surface. There was no hemorrhage or necrosis (Figure A, B, and C). The patient was discharged 2 days after surgery without complication. No evidence of recurrences was noted after 4 months.

DISCUSSION: The most frequent reason to come gynecology polyclinics is itching and burning. Many

benign vulvar tumors are asymptomatic and are found only incidentally. Even if treatment or excision is usually not required, differential diagnosis should be considered and the diagnosis should be confirmed that includes pre- and malignant tumors. One of the rare of these lesions is schwannomas. Schwannomas are benign, slow-growing tumors that infrequently recur and rarely undergo malignant change. Although vulvar schwannomas are rare, clitoral schwannomas are even rarer. Schwannomas, neurofibromas, and perineuromas are a group of mostly benign tumors of clitoris. Treatment in the form of excision is accepted to be curative (1). Although schwannomas are peripheral nerve tumor sheaths, they are very rare. There are only 6 clitoral schwannoma cases in the literature (Table 1). **CONCLUSION:** Genital schwannoma should also be considered in the differential diagnosis in women with clitoral or paraclitoral asymmetric, irregular, slow-growing masses.

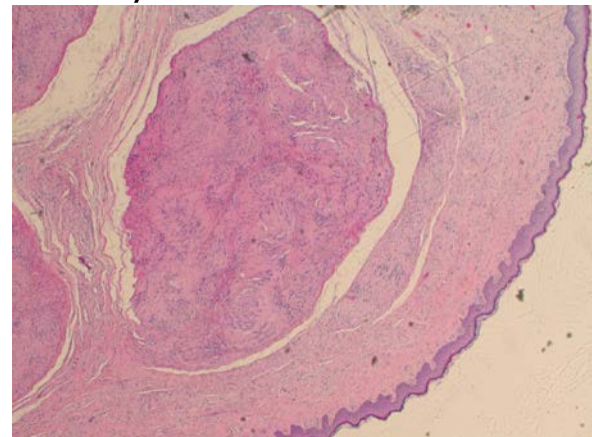
Keywords: clitoral mass, excision, schwannoma

FIGURE1/A



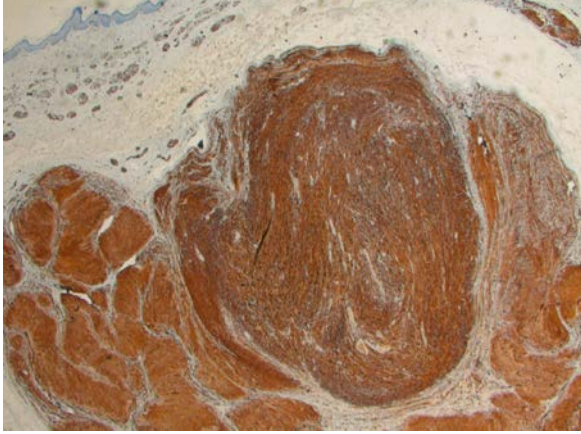
H&E section of the lesion

FIGURE1/B



H&E section of the lesion

FIGURE1/C



S-100 section of the lesion

TABLE1

Age/ Sex	Size	Clinical Follow-up	NF/ Virilization	IHC	Benign/ Malign	FH	Reference
41/F	20X20MM	NED, 2 YEARS	None	S100+	B	None	3
64/F	30X30MM	NR	None	S100+	B	None	4
6/F	20X30MM	NR	None	S100+	B	None	5
76/F	20X17MM	NED, 1 YEARS	None	NR	B	Sister (Lung CA)	7
1/F	40X20MM	NED, 30MONTHS	NF +	NSE+ MBP+ S100- S100+	M	Mother (acoustic neuroma)	9
38/F	150X60MM	NED, 4 MONTHS	None	S100+	B	None	12

Review of literature

SS-54

Endometrial carcinoma presenting with isolated humeral fracture: A case report

Ömer Alp Yavuz¹, Hasan Volkan Ege², Onur Atakul¹,
Zafer Selçuk Tuncer², Derman Basaran²

¹Department of Obstetrics and Gynaecology, Hacettepe University, Ankara, Turkey

²Department of Obstetrics and Gynaecology, Division of Gynaecologic Oncology, Hacettepe University, Ankara, Turkey

Endometrial cancer is known as the most common gynecological cancer in developed countries. Vaginal bleeding is the most common complaint, and the diagnosis is made in the early stages in most patients. However, advanced endometrial cancer present can with vaginal bleeding, it is also presented with atypical presentations.

In advanced endometrial cancer, the most common site of metastasis outside the pelvis are the lung and liver. Bone metastases are very rare.

In this study, we present a rare case of endometrial cancer diagnosed with a pathological bone fracture.

Case Report

77 years old, female patients apply to the orthopedics clinic with right arm pain and a right humeral proximal fracture is detected. The patient operated and a sample taken from a fracture is reported as adenocarcinoma metastasis as a result of pathology. The patient, who described vaginal bleeding in the last 6 months, was referred to the gynecology department for malignancy screening as a result of the pathology report.

After gynecologic examination, endometrial biopsy performed and reported as grade 2, endometrioid type endometrial carcinoma. PET-CT performed to the patient revealed increased FDG uptake in the proximal right humerus, lateral left clavicle and right femur. In addition, intense FDG uptake was detected in the uterine corpus and in the distal 1/3 of the vagina (Figure-1).

Total abdominal hysterectomy + bilateral salpingoophorectomy + bilateral pelvic lymph node dissection+ vaginal mass excision is performed. The diagnosis of endometrioid type grade 2 adenocarcinoma was confirmed in the final pathology report. Metastasis was detected in the left external iliac lymph node and vaginal mass.

After final pathology report adjuvant chemotherapy (carboplatin+paclitaxel) were administered. The patient died 5 months after diagnosis.

Conclusion: Incidence of bone metastases in endometrial cancer is approximately 1%. Common sites of bone metastasis in endometrial cancer are spine and pelvic bone. Bone metastases at extremities are rare. In addition, bone metastases at presentation with endometrial cancer are even more uncommon. There may be a risk of bone metastasis in patients with endometrial cancer, and the disease may present with bone-related complaints, although rarely, as in our case.

Keywords: Bone Metastases, Endometrial Cancer, Humerus Fracture

SS-55

Spontaneous triple pregnancy after tubal sterilization: case report

Ebru Kaynar varlık, Ulku Mete Ural, Elif Betül Esmer, Pelin Oyadı
Department of Gynecology and Obstetrics, Abant İzzet Baysal University, Bolu, Turkey

INTRODUCTION: Tubal Sterilization is performed at the request of women who have completed childbearing and want an effective and permanent method of birth control. It may be done at any time during a woman's menstrual cycle as well as in the immediate postpartum or postabortal period (1). Apart from contraceptive benefits, tubal ligation operations have advantages including a potential reduction of pelvic inflammatory illness and epithelial ovarian cancer (2). In this article, we aimed to present a case of spontaneous triple pregnancy in a patient who underwent laparoscopic tubal ligation.

CASE: The 37-year-old patient, G: 5 P: 5, had a laparoscopic tubal ligation operation at an external center on the 11th day of her menstrual cycle. The patient, whose preoperative b-hCG value was negative, applied to our clinic with pregnancy complaints such as nausea and fatigue. In the ultrasonographic evaluation, 3 gestational sacs were observed in the endometrial cavity. There was no history of multiple pregnancy in the patient's medical history. The patient, who did not want to terminate her pregnancy, was taken into routine pregnancy follow-up. The patient, whose pregnancy follow-up was normal, gave birth to three healthy female babies weighing 2085 g, 1990 g and 1440 g by cesarean section at the 34th week of pregnancy.

DISCUSSION: Tubal sterilization, whether carried out postpartum or as laparoscopic procedure, has a known risk of failure. It is important to discuss that it does not provide 100% protection. Common methods of laparoscopic tubal sterilization include unipolar coagulation, bipolar coagulation, partial salpingectomy, and mechanical occlusion techniques using clips or rings (3).

Early studies of sterilization failure were short-term in nature; subjects were followed for 12 to 24 months after the procedure, and failure rates of 0.2–0.5% were identified (4). According to the CREST study (The U.S.

Collaborative Review of Sterilization) the first long-term investigation of the failure risk of sterilization, the 10-year failure rate is 18.5 per 1000 procedures (all procedures aggregated). This multicentre prospective cohort study identified 10,685 women who were assessed 5 to 16 years post-sterilization. Cumulative 10-year probabilities of pregnancy were highest after clip sterilization (36.5/1000 procedures) and lowest

after unipolar coagulation (7.5/1000) and postpartum partial salpingectomy (7.5/1000). The cumulative risk of pregnancy was highest among women sterilized at a young age with bipolar coagulation (54.3/1000) and clip application (52.1/1000) (5).

Only one case of multiple pregnancy after tubal ligation has been reported in the literature, and this was a twin pregnancy (6). The unique aspect of our case is that a spontaneous triple pregnancy occurred after tubal ligation and this situation has not been reported before.

Patients should be warned about the possibility of pregnancy after tubal ligation and the risks associated with the procedure should be discussed with the patient in detail and informed consent should be obtained. Pregnancy suspicion should be questioned before the procedure. If possible, the procedure should be performed on the day of the cycle when pregnancy is least likely. Patients should, therefore, be counseled to present early if they suspect pregnancy.

Keywords: triple pregnancy, tubal sterilization, tubal ligation

üçüzler



SS-56

Investigation of factors affecting recurrence in locally advanced cervical cancer

Fazıl Avcı, Ahmet Bilgi, Çetin Çelik
Selçuk University Faculty of Medicine, Department of Obstetrics and Gynecology, Konya, Turkey

OBJECTIVE: To investigate the factors affecting recurrence in locally advanced cervical cancer (LACC).

MATERIAL-METHODS: This retrospective study included cases diagnosed with LACC (II-IVA 2018 FIGO) between December 2010 and April 2022 at Selçuk University Faculty of Medicine. A total of 90 cases were evaluated, including 70 cases without recurrence (group 1) and 20 cases with recurrence (group 2). Magnetic Resonance Imaging (MRI) was used as the imaging method. Clinicopathologic and survival data were statistically analyzed according to the recurrence rate.

RESULTS: The mean ages of groups 1 and 2 were 60.4 ± 12.1 and 56.0 ± 10.4 years, respectively, with no statistically significant difference. There were no statistically significant differences between the two groups in terms of smoking, MRI lesion diameter (mean, 2 cm, and 5 cm), histologic type, staging method (extraperitoneal or MRI), number of pelvic and para-aortic lymph nodes, radiotherapy method (pelvic and pelvic-para-aortic), and treatment protocol. There were statistically significant differences between the two groups in terms of stage (stage 2, 3 and 4, response to adjuvant treatment, disease-free survival and overall survival). Of the recurrences, 13 were local (65%), 4 were local+ distant (20%) and 3 were distant (15%). The most common distant recurrence sites were lung in 3 cases, bone in 2 cases, liver in 1 case and multiple metastases in 1 case. The median recurrences were local at 10 months, local+ distant at 12 months and distant at 15 months. In the treatment of recurrences, chemotherapy (CT) was given in 7 cases, surgery and CT in 5 cases, CT+ palliative radiotherapy (RT) in 3 cases, palliative RT in 1 case and supportive treatment in 4 cases.

DISCUSSION: Stage IB3-IVA cervical cancer is defined as LACC. Approximately 75% of the pathologic types of cervical cancer are squamous cell carcinoma. The current standard of care is radical concurrent chemoradiotherapy (CCRT). The median 5-year overall survival (OS) rate with CCRT treatment was 40-50%, 29-38% of failures were uncontrolled and recurrent, and the 5-year survival rate of patients with recurrent tumors was only 3.8 - %13,0 (1). Binbin et al. (2) found that 5 years after concurrent chemoradiotherapy, OS and PFS rates were 75.9% and 71.7%, respectively, for patients with stage IIB and 52.9% and 42.8%, respectively, for patients with stage \geq III. A Korean study (3) found that 5-year

survival rates after concurrent chemoradiotherapy were 71.5% for patients in stage IIB, 44.9% for patients in stage III and 20.9% for patients in stage IVA.

CONCLUSION: Stage is the most important factor affecting recurrence in locally advanced cervical cancer. Since recurrences are frequently detected in the first 24 months, early diagnosis and treatment of recurrences may reduce mortality and morbidity.

Keywords: cervical cancer, MRI, recurrence, staging

Comparison of locally advanced cervical cancer cases according to recurrence

Table 1: Comparison of locally advanced cervical cancer cases according to recurrence

		Group 1 (n=70)	(%)	Group 2 (n=20)	(%)	p value
Age, year		60.4 \pm 12.1		56.0 \pm 10.4		0.141
Cigarette use	No	58	82.9	15	75.0	
	Yes	12	17.1	5	25.0	0.310
MRI mass mean, mm		41.7 \pm 18.4		50.1 \pm 18.0		0.072
MRI mass size, mm	\leq 20	12	17.1	1	5.0	0.158
	>20	58	82.9	19	95.0	
MRI mass size, mm	\leq 50	47	67.1	11	55.0	0.229
	>50	23	32.9	9	45.0	
Histology type	Squamous	66	94.3	18	90.0	0.675
	Adeno	1	1.4	1	5.0	
	others	3	4.3	1	5.0	
Staging choice	Surgery	31	44.3	9	45.0	0.576
	Imaging	39	55.7	11	55.0	
Stage	II	24	34.3	4	20.0	0.034
	III	37	52.9	8	40.0	
	IV	9	12.9	8	40.0	
Pelvic lymph node, number		5 (0-42)		3 (0-27)		0.475
Para-aortic lymph node, number		9 (2-24)		9 (3-18)		0.642
Radiotherapy modality	Pelvic	61	87.1	19	95.0	0.297
	Pelvic and Para-aortic	9	12.9	1	5.0	
Treatment protocol	Only radiotherapy	2	2.9	2	10.0	0.213
	Konkumutan CRT plus brachittherapy	68	97.1	18	90.0	
Response to therapy	Progression	0	0	2	10.0	0.001
	<%30	0	0	2	10.0	
	%30-50 regression	3	4.3	5	25.0	
	%50-80 regression	1	1.4	0	0	
	Tumor-free complete response	66	94.0	11	55.0	
Recurrence duration, month	Local	-		10 (4-30)		
	Distant	-		15 (7-37)		
	Local+distant	-		12 (6-20)		
DFS, month		110.5 \pm 7.3 (96.3-125.0)		15.1 \pm 2.1 (11.2-26.6)		0.001
OS, month		111.6 \pm 7.0 (97.8-125.5)		27.5 \pm 4.4 (19.0-36.1)		0.001

Table 1

Figure 1: OS analysis of cases according to recurrence

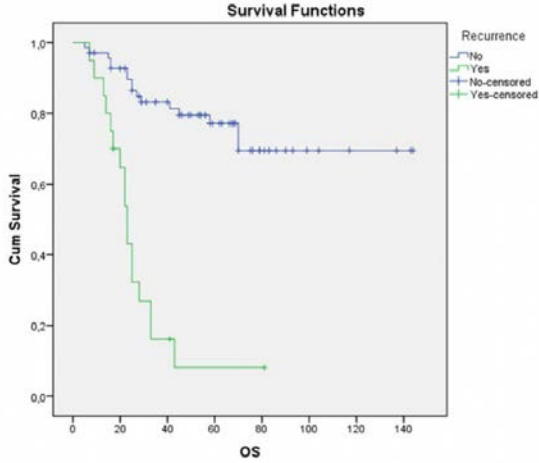


Figure 1

Olguların rekürrense göre DFS analizi

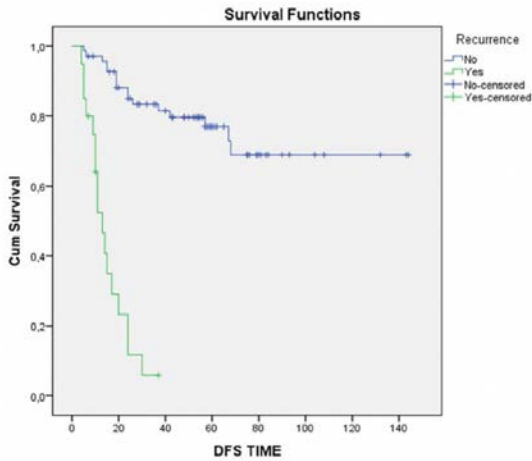


Figure 2

Characteristics of recurrence cases

		(n=20)	(%)
Localization site			
	Local	13	65
	Distant	3	15
	Local+distant	4	20
Metastasis site			
	Lung	3	42,9
	Liver	1	14,3
	Bone	2	28,6
	Multiple	1	14,3
Treatment			
	CT	7	35
	CT+ Palliative RT	3	15
	Surgery ve CT	5	25
	Palliative RT	1	5
	Support	4	20

Table 2



5. Jinekoloji ve Obstetrikte Tartışmalı Konular Kongresi

5-8 Ekim 2023 | Hilton Dalaman Sarıgerme

SS-58

Pregnant woman with cystic fibrosis with severe lung failure, case report

Merve Şaya, Emrullah Akay
Başakşehir Çam ve Sakura Şehir Hastanesi, İstanbul

Cystic fibrosis (CF) is an inherited autosomal recessive disease with a worldwide incidence of 1 in between 2,000 and 5,000 live births. Cystic fibrosis patients may present with recurrent respiratory infections, bronchiectasis, progressive deterioration of the lung function, exocrine pancreatic insufficiency, and CF-related diabetes. The life expectancy of CF patients has increased markedly in the recent decades. Currently, the predicted survival of an American CF patient is of 41.7 years. As the life expectancy and the quality of life improve, the pregnancy rate has also been increasing. The first described pregnancy in a woman with CF resulted in a preterm newborn and in maternal death 6 weeks after the delivery. Subsequent studies showed poor maternal outcomes and high prematurity and miscarriage rates.

Our patient is 27 years old, gravida 2, parity 1. Her first pregnancy resulted in fetal death at 20 weeks. She had a history of frequent hospitalizations due to recurrent bronchiectasis. She presented to our hospital with dyspnea at 20 weeks gestation. Vital signs were saturation 69, blood pressure 115/92 mmHg, pulse rate: 138 beats/minute. Fetal heartbeat was present and compatible with the fetal developmental week. The patient was hospitalized in our intensive care unit. While she was intubated during admission, she was connected to extracorporeal membrane oxygenation (ECMO) device due to the development of pulmonary insufficiency. We terminated the pregnancy by cesarean delivery due to fetal death on the 2nd day of ECMO treatment. She was weaned from ECMO in the second week. She was extubated in the fourth week of hospitalization.

Cystic fibrosis patients with severe lung impairment may achieve successful term pregnancies. Cystic fibrosis patients should be followed by a specialized team with experience in treating respiratory diseases. Close surveillance, aggressive management, and a team approach can result in successful pregnancy outcome in those women with cystic fibrosis.

Keywords: Cystic fibrosis, pregnancy, miscarriage

SS-59

Ovarian Torsion in the Third Trimester of Pregnancy with Indistinct Clinical Findings

Ayşenur Akkoç, Gülten Nilda Nalbant, Oğuzcan Karagöz, Derya Kilic
Pamukkale University, Denizli, Turkey

AIM: Ovarian torsion during pregnancy is a rare condition, with most cases occurring in the first trimester. Diagnosis depends on physical examination findings, along with the utilization of ultrasound (USG) and magnetic resonance imaging (MRI). This case report presents an unusual occurrence of ovarian torsion in the third trimester and highlights the diagnostic challenges associated with it, contributing valuable data to the existing knowledge.

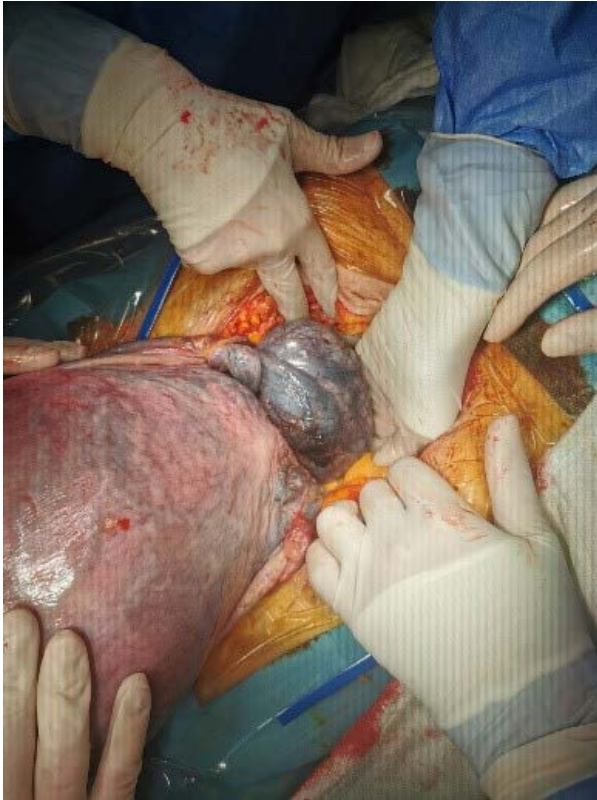CASE: She had previously experienced two vaginal deliveries with an unremarkable obstetric history and no prior ovarian cysts or ovulation induction. She described severe, sudden-onset, diffuse abdominal pain without urinary or gastrointestinal symptoms. On abdominal examination, tenderness was noted in the right lower quadrant, while obstetric evaluation showed normal findings with a well-toned uterus. Ultrasound confirmed fetal well-being, including cardiac activity, fetal movements, and amniotic fluid. Vital signs were as follows: blood pressure 99/65 mm Hg, pulse rate 104 bpm, and temperature 36.5°C. Laboratory results revealed a white blood cell count of 8.35, hemoglobin level of 9.3, and C-reactive protein level of 3.2. Platelet count and urinalysis were within normal limits. Ultrasonographic examination was limited due to the presence of the uterus, preventing visualization of the ovaries, and an abdominal ultrasound failed to visualize the appendix for similar reasons. An MRI revealed a simple cystic lesion measuring 75x52 mm in the right adnexa, with no characteristics suggestive of fat or bone seen in dermoid tumors. A small amount of free fluid was present around the cyst (Figure1). Due to the persistence of the patient's pain and the development of acute abdominal symptoms during follow-up, diagnostic laparotomy was performed, revealing a two full twists of the right ovary along with the fallopian tube (Figure 2). Successful detorsion was achieved. Close monitoring of the fetus before and after the surgery showed no obstetric or fetal complications. The patient was discharged on the third day post-operation. At 37 weeks of gestation, she went into labor, and a healthy delivery was achieved via cesarean section.

CONCLUSION: Ovarian torsion during pregnancy is a rare and emergent condition that can lead to venous and arterial blood flow disruption, resulting in ischemia and necrosis. The estimated prevalence of

ovarian torsion during pregnancy is 1.6-4 per 10,000 pregnancies. Most cases occur in the first trimester (55.3%), followed by the second trimester (34.2%), with third-trimester cases being less common (10.5%). Due to the less distinctive clinical presentation of acute abdominal conditions in the third trimester, clinicians should maintain a high index of suspicion for ovarian torsion in their differential diagnosis.

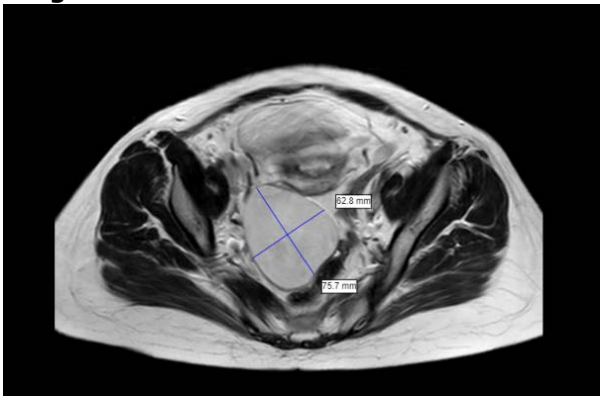
Keywords: pregnancy, ovarian torison, abdominal pain

intraoperatif görüntüsü



vakaya ait intraopertif resim

mr görüntüsü



olguya ait mr görüntüsü

SS-60

Comparison of change in retrovesical angle during valsalva between women with isolated urgency symptoms and asymptomatic women

Elif Avşaroğlu, Tülay Semiz, Mesut Özer, Derya Kılıç
Department of Obstetrics and Gynecology, Pamukkale University, Denizli, Turkey

AIM: There has been an ongoing debate regarding the association of irritable bladder with anterior vaginal wall defects. Previous studies are limited to inclusion of heterogeneous group of women with varying degree of prolapse and other urinary symptoms (1). Therefore, in this study we aimed to investigate women without stress urinary incontinence (SUI) regarding to the change in retrovesical angle (RVA) during valsalva.

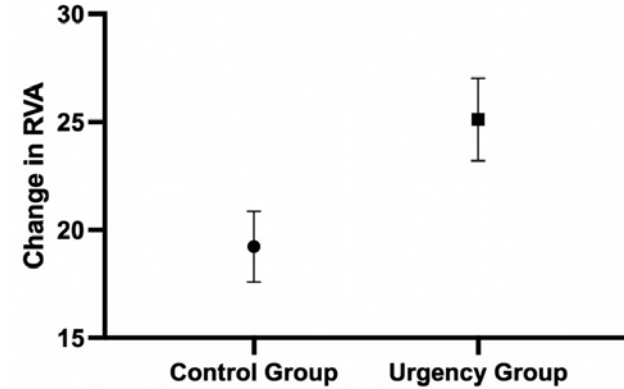
METHODS: Patient files of women with detailed urogynecological examination including dynamic pelvic floor ultrasonography findings were reviewed. Exclusion criteria were as: women having previous urogynecological operation, women having symptoms of SUI, women having neurological disease, and women with a anterior prolapse (Aa or Ba) greater than -1 score. Study and control group were defined according to urgency presence.

RESULTS: Totally 34 women with urgency fulfilling the study criteria were retrieved. Age and body mass index matched 34 asymptomatic women were defined as the control group. Baseline characteristics of the groups are presented in Table 1. Change in RVA after valsalva was found to be greater in the Urgency group than that of in the control group (25.12 ± 11.15 vs. 19.23 ± 9.51 , $p=0.022$) (Figure 1).

CONCLUSION: Uretral rotation angles were previously documented to be altered in women with SUI (2). According to the 'integral theory of pelvic floor dysfunction' that was first proposed before 21st century by Peter Petros and Ulf Ulmsten, it was stated that anterior vaginal wall relaxation is associated with symptoms of urgency (3). Since previous studies were limited to inclusion of heterogeneous group of women, in this study we utilized strict inclusion criteria as focusing on women without SUI and overt anterior prolapse. In this group of women we documented that women with urgency had greater RVA change after valsalva when compared to the control groups. This finding is parallel to the proposal of Integral Theory stating the association of urgency and anterior vaginal wall relaxation.

Keywords: urgency, urinary incontinence, retrovesical angle

Comparison of RVA between two groups.



RVA: Retrovesical angle

Baseline characteristics of the study population

	Control group	Urgency group	P value
Age (years)	45.47 ± 9.19	49.68 ± 12.80	0.124
BMI (kg/m ²)	27.19 ± 2.91	28.47 ± 3.88	0.149
Gravida	2.91 ± 1.16	2.76 ± 1.9	0.712
Vaginal delivery number	2.06 ± 1.49	2.12 ± 1.65	0.878

BMI: Body mass index

SS-61

Pemphigoid Gestationis and Fetal Distress: A Rare Case and Examination of Neonatal Symptoms

Büşra Tsakir, And Yavuz

Perinatology department, Antalya training and research hospital, Antalya, Turkey

AIM: To investigate Pemphigoid Gestationis (PG), a rare autoimmune skin disease with an incidence of 1 in 50,000, and a rare complication of this disease, fetal distress.

METHODS: This case report constitutes a retrospective analysis focusing on single case. The research was conducted with the aim of examining the clinical history and treatment process of one patient.

FINDINGS: The patient was a 22-year-old woman with a gestational age of 27 weeks. Her complaints included severe pruritic, edematous red lesions that had started approximately a week ago and spread across her body. These symptoms had never occurred before, and there was no history of drug or food allergies. She had hypothyroidism and gestational diabetes during pregnancy. During the exam, sequential erythematous vesicles were seen on her body. Metilprednisolon 32

mg/day treatment started. While our case aligns with typical timing, extremity lesions are atypical. This case report highlights facial involvement, which is uncommon in PG cases where lesions typically occur on the trunk. This suggests a potentially severe and widespread disease course. There is no literature data on the incidence of a disease causing such severe involvement of the entire body. Biopsy results showed pathological findings, and Anti-BP180 (IgG1) antibodies were measured, confirming the diagnosis of PG.

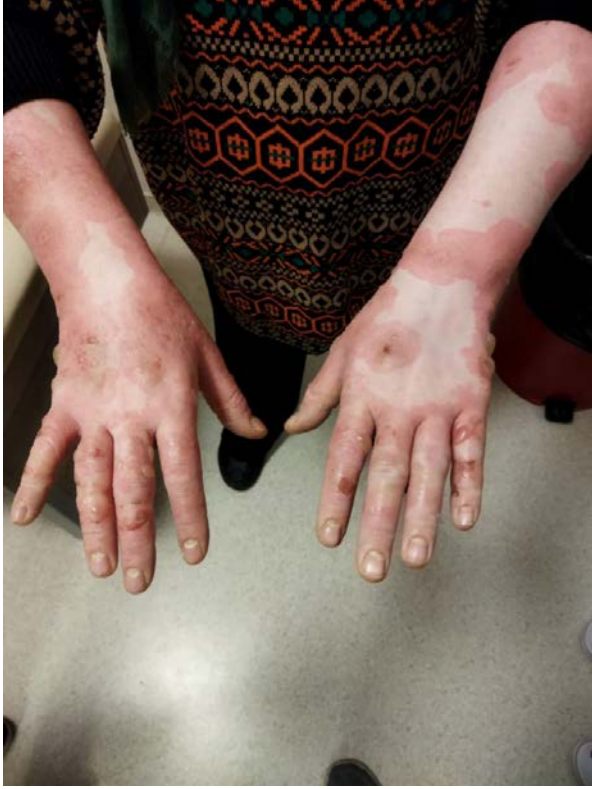At the 34th week of pregnancy, an emergency cesarean section was performed due to fetal distress detected during routine non-stress testing, resulting in the birth of a female infant weighing 2130 grams and measuring 48 cm with Apgar scores of 9/10 at 1 minute and 5 minutes after birth. Fetal distress is another notable factor in this case report. The effects of PG on the fetus typically focus on conditions such as placental insufficiency, intrauterine growth restriction, prematurity. However, fetal distress isn't commonly seen as a complication in PG cases. The sudden appearance of fetal distress in this case report suggests that the effects of the disease on the fetus may be more serious, potentially leading to the early termination of pregnancy.

After the patient gave birth, mild erosions were observed on the baby's face, but these lesions were not prominent during the first 2 days. Widespread lesions on the baby's body appeared 2 days later, and stayed in the neonatal intensive care unit for 12 days, and improvement in the lesions was observed after approximately 20 days without treatment. It's important to note that lesions appeared inconspicuously in the initial 3 days after birth, highlighting the delayed impact of pemphigoid gestationis on neonatal symptoms and variable clinical timing. The mother experienced a postpartum flare, and the steroid dose was increased to 64 mg/day. Follow-up visits showed no new lesions, and steroid treatment was gradually reduced and discontinued within 2 months.

RESULTS: This specific case report emphasizes that the clinical course of PG can vary for each patient, and unexpected complications can arise. Therefore, close monitoring, multidisciplinary management, and special attention to the fetal condition are essential for patients diagnosed with PG.

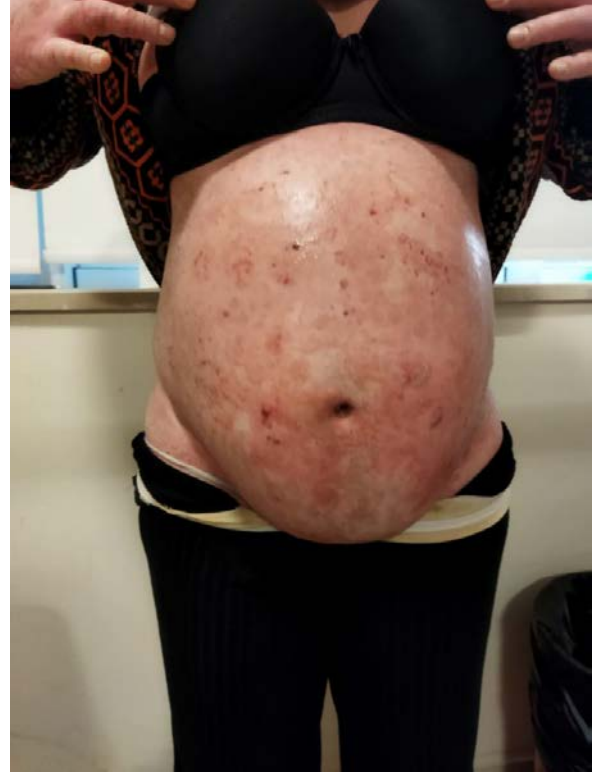Keywords: Autoimmune Skin Disease, Fetal Distress, Pemphigoid Gestationis (PG)

1. Skin Lesions on Mother's



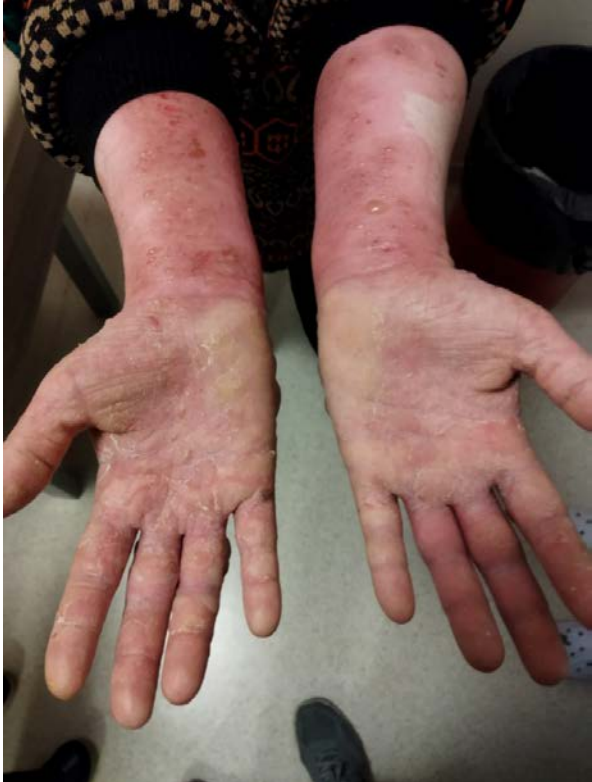Erythematous Skin Lesions on Mother's Hands and Palms

3. Skin Lesions on Mother's



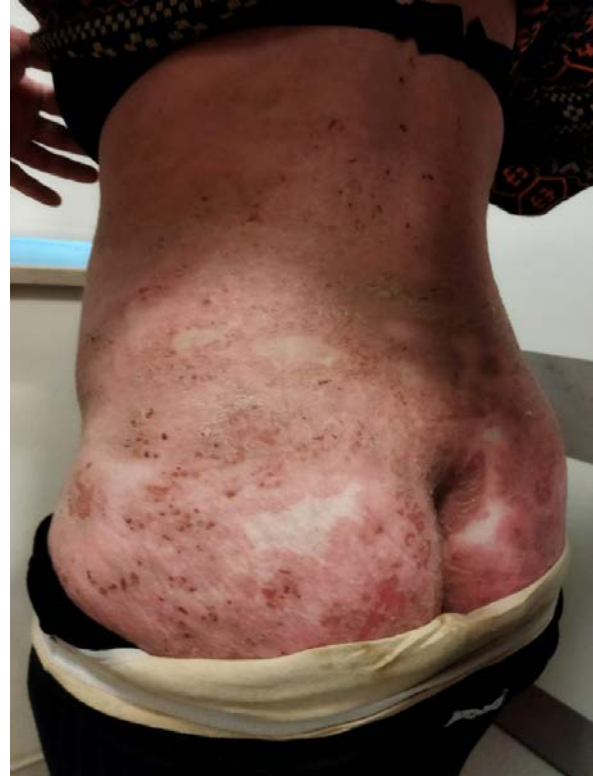Urticarial Plaques and Bullae Present on the Abdominal Periphery

2. Skin Lesions on Mother's



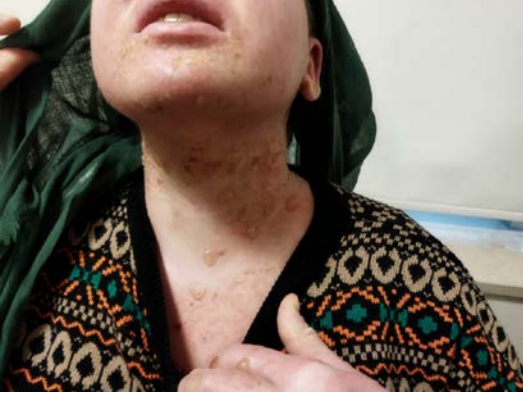Erythematous Skin Lesions on Mother's Hands and Palms

4. Skin Lesions on Mother's



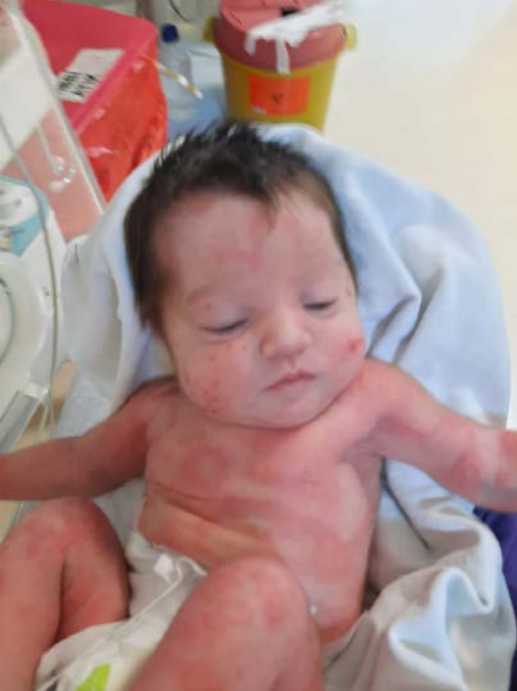Pemphigus lesions on the gluteal (buttock) and back regions are characterized by blistering, erosions, and redness

5. Skin Lesions on Mother's



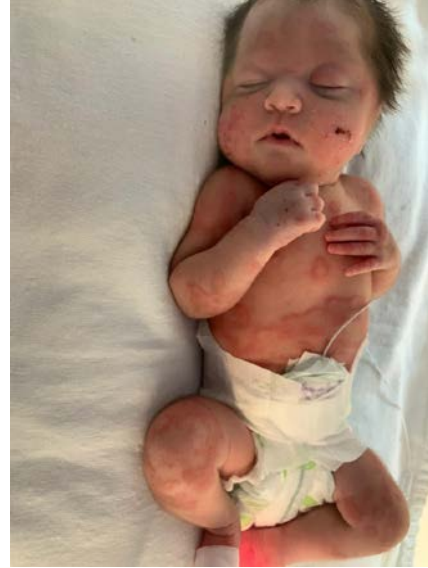The rare pemphigus lesions on the face manifest as localized blistering and erosions of the skin.

Newborn 4th day



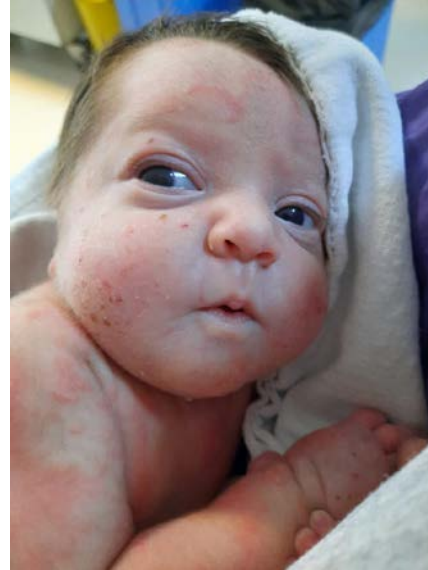onset of pemphigus plaques and erythema on the 4th day

Newborn 5 th day



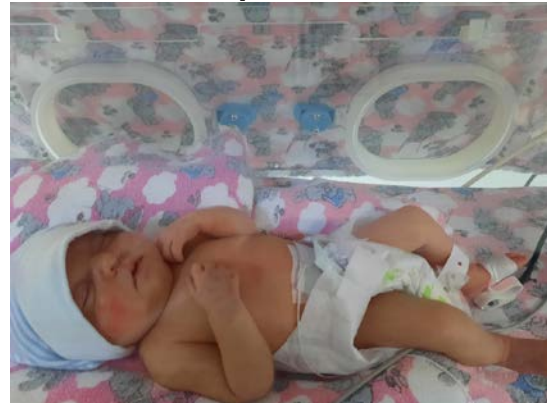spread of the skin condition across the entire body on the 5th day

Newborn 6th day



the facial lesions beginning to crust on the 6th day

Newborn first day



newborn without lesions on the first day,



5. Jinekoloji ve Obstetrikte Tartışmalı Konular Kongresi

5-8 Ekim 2023 | Hilton Dalaman Sarıgerme

SS-62

A case report of intractable severe hyponatremia associated with preeclampsia

Yasemin Doğan¹, Ercan Koçkaya², Mert Doğan Filinde², Müzeyyen Dilşad Eser²

¹Department of Perinatology, Kocaeli University School of Medicine, Kocaeli, Turkey

²The Department of Obstetrics and Gynecology at the University of Kocaeli, Kocaeli, Turkey

Preeclampsia is a grave medical condition that affects multiple organs and systems in pregnant women. Although it is usually characterized by hypertension and proteinuria, the disease may manifest through elevated levels of aspartate aminotransferase (AST)/ alanine aminotransferase (ALT), low platelet counts, increased urea creatine, epigastric pain, persistent headache, pulmonary edema, and visual disturbances. Rarely hyponatremia can accompany severe preeclampsia. The aim of this presentation is to elucidate a case involving severe hyponatremia in association with preeclampsia, a condition whose underlying etiopathogenesis remains unclear.

A 30-year-old, 26 weeks pregnant, primigravid patient was referred to our clinic with hyponatremia (120 mEq/L), hypocalcemia (6.8 mg/dL), thrombocytopenia (plt:100 000/ μ l), proteinuria (+3 proteinuria in spot urine).

Prior to referral, the patient had diarrhea, nausea, and vomiting for a period of four days and she had received intravenous calcium gluconate, 3% hypertonic sodium chloride, and furosemide. After hospitalisation, the results of the complete blood count and biochemistry revealed a sodium level of 124 mEq/L, calcium level of 8.8 mg/dL, platelet count of 89000/ μ l, AST level of 32 U/L, ALT level of 29 U/L, urea level of 24.9 mg/dL, creatinine level of 0.74 mg/dL, lactate dehydrogenase (LDH) level of 268 U/L, and a blood pressure reading of 120/80 mmHg. Furthermore, the patient exhibited +2 pretibial edema. After nephrology consultation, the recommended course of treatment included saline infusion, with sodium levels to be monitored every 6 hours and not to exceed an increase of 10 mEq/L per day. The patient's 24-hour urine protein was 2754 mg/day. Urine sodium level and urine osmolality was normal (87 mmol/L, 510.2 mosm/kh respectively). On the 2nd day of follow-up, hyponatremia deepened (119 mEq/L) and 3% hypertonic saline infusion was started. On the 5th day of follow-up, the patient presented with significant vulvar edema and na level sodyum is 114 mEq/L. Echocardiography of the patient revealed tricuspid regurgitation due to hypervolemia, dilatation in the right atrium and pericardial effusion. On the 11th day of follow-up, hyponatremia persisted despite saline infusion with

a recorded sodium level of 112 mEq/L. The presence of orthopnea, pleural effusion in the chest radiograph, and a blood pressure of 140/90 mm Hg were indicative of severe preeclampsia so cesarean delivery was planned at 28th gestational week. Postoperative blood pressure was 180/110 mm Hg and Glasgow coma score was low 9. Cranial magnetic resonance imaging was normal. Blood sodium was 130 mEq/L on the first postoperative day and 140 mEq/L on the fourth postoperative day. Vulvar edema regressed and blood pressure was stable and she was discharged on postoperative 7th day. Preeclampsia can be associated with hyponatremia related to the impaired renal function and altered fluid balance. Hyponatremia can have serious consequences including seizures and cerebral edema. Therefore, prompt recognition and management of hyponatremia in cases of preeclampsia are essential to ensure optimal maternal and fetal outcomes. Dramatic improvement following delivery is expected.

Keywords: Preeclampsia, Hyponatremia, pregnancy

SS-63

Ovarian ectopic pregnancy after in vitro fertilization

Mücahit Furkan Balcı¹, Bayram Özağaç¹, Ece Cahide Cahide Uğur Özizmirli¹, Begüm Özcan¹, Yaşam Kemal Akpak²

¹izmir tepecik training and research hospital, gynecology and obstetrics clinic, izmir, turkey

²health sciences university,,izmir faculty of medicine, gynecology and obstetrics clinic, izmir, turkey

Ovarian ectopic pregnancy develops as a result of fertilization of the ovum in the ovary or secondary implantation of the fertilized ovum in the ovary. Ovarian ectopic pregnancies after assisted reproductive techniques develop as a result of secondary implantation of the embryo in the ovary. In this case report, a patient with an ovarian ectopic pregnancy after in vitro fertilization(IVF) is presented to shed light on the diagnosis and treatment for clinicians.

A thirty two year old primigravida patient, who had been complaining of abdominal pain for the past week, was admitted to the emergency department. The patient, who was undergoing treatment for infertility, had undergone embryo transfer six weeks ago. On examination, the patient displayed tachycardia, hypotension, widespread abdominal pain, and signs of an acute abdomen. Laboratory results revealed a human chorionic gonadotropin level of 2385 mIU/ml, hemoglobin level of 8.4 g/dL, Ultrasonography showed no gestational sac within the uterus, but a right adnexal gestational sac

5. Jinekoloji ve Obstetrikte Tartışmalı Konular Kongresi

5-8 Ekim 2023 | Hilton Dalaman Sarıgerme

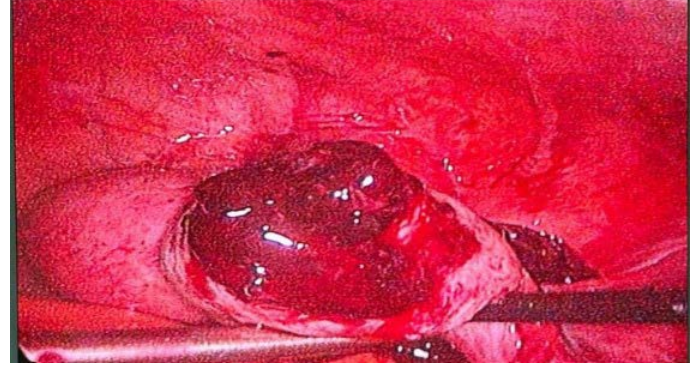
measuring 3cm×3 cm× 2 cm was observed along with extensive free fluid. The preliminary diagnosis was a ruptured ectopic pregnancy, and emergency operative laparoscopy was planned for the patient.

Intraoperatively, the uterus size and both fallopian tubes were normal. Hemoperitoneum was detected. The right ovary was enlarged with a hemorrhagic mass of size 3x4 centimeters. A right partial oophorectomy was performed and the content was sent to histopathology. Subsequently, the ovarian region was sutured intracorporeally. The bleeding was controlled. The postoperative period was uneventful. Ovarian pregnancy was confirmed by reporting trophoblastic villi and corpus luteum embedded in the ovarian tissue on histopathological examination.

Ovarian pregnancy is a rare form of ectopic pregnancy. The prevalent clinical symptoms are abdominal pain and vaginal bleeding. Difficult to diagnose ovarian pregnancy preoperatively. In cases of early diagnosed ovarian pregnancy, the primary treatment should be a conservative surgical approach, taking into account the desire for future fertility. Medical treatment approaches, such as methotrexate for ovarian pregnancies, should only be considered in the presence of persistent trophoblastic tissue after surgery. However, in larger ovarian ectopic pregnancies where the ovary is severely damaged, oophorectomy may be required instead of conservative surgery to control bleeding. Although this patient had severe intraabdominal bleeding, the ectopic pregnancy focus in the ovary was completely removed by the laparoscopic method, and a significant amount of residual ovarian tissue could be preserved. Bleedings should not be considered a contraindication for laparoscopy in these patients as long as vital signs are stable. To control bleeding in the laparoscopic approach, the ovarian tissue must be sutured. Patients suspected of having an ovarian ectopic pregnancy who will undergo laparoscopic surgery should be operated on by a team familiar with laparoscopic suturing techniques. Otherwise, the laparotomic approach should be preferred. Although ovarian pregnancy is a rare form of ectopic pregnancy, its diagnosis can have a more negative impact on fertility than tubal ectopic pregnancies. Therefore, it is significant to diagnose ovarian ectopic pregnancies and protect the ovary through a conservative surgical approach. Ovarian ectopic pregnancy after in vitro fertilization.

Keywords: ectopic, IVF, Pregnancy

operasyon sırasında overe implante ektopik gebelik dokusu



operasyon sırasında overe implante ektopik gebelik dokusu

SS-64

The sensitivity of ultrasonography in the diagnosis of hydatidiform mole and the contribution of laboratory findings to the diagnosis

Mücahit Furkan Balcı¹, Ece Cahide Uğur Özizmiriler¹, Zeliha Öcal¹, Burcu Ceren Seferoğlu¹, Yaşam Kemal Akpak²

¹izmir tepecik training and research hospital, gynecology and obstetrics clinic, izmir, turkey

²health sciences university,,izmir faculty of medicine, gynecology and obstetrics clinic, izmir, turkey

Aim: In this study, we aimed to evaluate the diagnostic sensitivity of ultrasonography and possible risk factors in patients who were suspected to have a hydatidiform mole on ultrasound and were diagnosed with hydatidiform mole as a result of the histopathological examination of the removed products of pregnancy.

Method: A retrospective analysis was performed of patients who applied to the Gynecology and Obstetrics Clinic of Tepecik Training and Research Hospital between 2017 and 2022, where the uterus was evacuated by therapeutic curettage after being evaluated ultrasonographically as a suspected hydatiform mole and examined histopathologically. Obtained laboratory findings, patient age, and gestational week were assessed together with histopathological results, and the sensitivity of ultrasonography in detecting hydatidiform mole and possible risk factors for hydatiform mole were determined.

Results: The number of patients included in the study was 522 pregnant women. All patients were evaluated ultrasonographically as suspicious for hydatidiform mole. In the histopathological examination of the material



5. Jinekoloji ve Obstetrikte Tartışmalı Konular Kongresi

5-8 Ekim 2023 | Hilton Dalaman Sarıgerme

after therapeutic curettage, 429 (82.2%) of the cases were diagnosed as hydatidiform mole. 93 (17.8%) of the patients were evaluated as usual abortion material and interpreted as no pathological findings in favor of molar degeneration. According to the histopathological examination of patients with a diagnosis of hydatidiform mole (429); 249 (58.04%) were partial moles and 180 (41.96%) were complete hydatidiform moles. The overall sensitivity for ultrasonographic diagnosis of hydatidiform mole was 82.2%. When women had histologically proven hydatidiform mole were compared with women whose sonographically suspected hydatidiform mole suspected but histologically excluded; there was no statistically significant difference in terms of mother's age ($p:0.198$) and gestational age ($p:0.13$). There was a statistically significant difference in terms of beta HCG levels ($p:0.03$) and TSH levels ($p:0.013$).

Conclusion: In this retrospective study, we analyzed the sensitivity of ultrasound in the diagnosis of hydatidiform mole. The results showed that ultrasound findings were more diagnostic when evaluated with TSH and Beta HCG levels in diagnosing hydatidiform mole. It was determined that low TSH levels and high Beta HCG levels could help the clinician in the diagnosis of hydatidiform mole, especially in ultrasonographically suspicious cases.

Keywords: mole, pregnancy, ultrasonography

SS-66

Presentation of a pregnant woman with acute abdomen at the 13th week of pregnancy who was previously followed up due to a complicated ovarian cyst

Elif Unluggedik Sayin, Tuğba Gül Yılmaz, Gazi Yildiz
Department of Obstetrics and Gynaecology, University of Health Sciences, Kartal Dr. Lütfi Kırdar Health Research Center, Istanbul, Turkey

Ovarian torsion is obstruction of the blood flow due to partial or complete rotation of the peduncle obtaining vessels of the ovaries. It's one of the most common emergencies of gynecological surgery(1). Torsion of the right ovary is more probable than the left ovary because the right utero-ovarian ligament is longer than the left one[2,3]. Predisposing risk factors include 5 cm or larger dimensions of the ovaries, mobility, long pedicle, and history of a previous ovarian torsion(4,5). Pregnancy also increases the risk of torsion(3). Here in, we aimed to present an ovarian torsion and its management in a 26-year-old pregnant woman during the first trimester.

A 26-year-old pregnant woman with gravida 1 had

a history of chemotherapy due to lymphoma and a previous surgery because of ovarian torsion. She was simultaneously followed up both in the gynecological oncology and perinatology outpatient clinics due to a complicated cyst from the beginning of the pregnancy. The patient described sharp and sudden onset of pain in the right lower quadrant at the 13th week of her pregnancy, she did not have diarrhea, constipation or fever.

Abdominal examination revealed severe tenderness, defense and rebound in the right lower quadrant. No bleeding or discharge was observed during the vaginal inspection.

Ultrasound of the abdomen showed CRL:13w+3d, single, live pregnancy, and a multilobular septal cystic formation in the right ovary measured 130x80 mm. Right ovarian blood flow was not seen. There were no pathological findings in the appendix lodge and no fluid in the abdomen.

Emergency laparotomy was performed under general anesthesia with the preliminary diagnosis of ovarian cyst torsion.

An approximately 150 mm necrosed ovarian cyst due to torsion was observed in the right ovary, there was serous fluid in the abdomen, uterus was about the size of a 12-week pregnancy, and the left ovary was macroscopically normal (Figures 1 and 2). The right ovary had rotated 4 full turns around itself.

A sample of the abdominal fluid was taken and sent for cytological examination. Due to gangrenous appearance of the ovary despite the detorsion of the mass, history of lymphoma and right ovarian torsion, and lack of frozen section during emergency conditions, we performed right salpingo-oophorectomy, and the material was sent for histopathological examination.

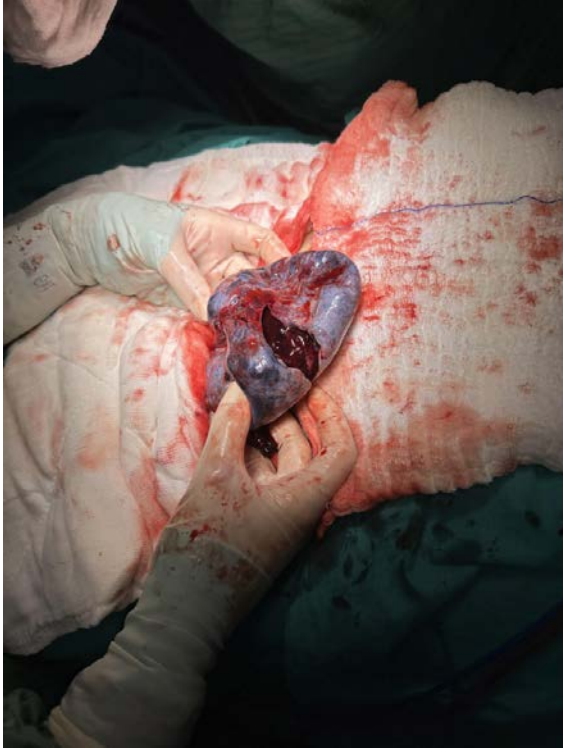The postoperative period was uneventful, and the patient was discharged on the 36th postoperative hour. Histopathological examination revealed a mucinous cystadenoma and hemorrhagic infarct in the left ovary, and no malignancy was observed in the intra-abdominal fluid. There were not any pregnancy-related complications during the first postoperative month, and the patient's ultrasound showed a live fetus compatible with its gestational age.

Although ovarian cysts are common during pregnancy, their management varies from patient to patient. The general approach is to follow up cysts that do not have complications or do not reveal clear malignancy criteria.

The incidence of ovarian torsion during pregnancy is unclear. In a series consist of 174 pregnant women with a persistent adnexal mass of 4 cm or more, the incidence of torsion was 15 percent and torsion was frequently observed between the 10th and 17th weeks of pregnancy(6).

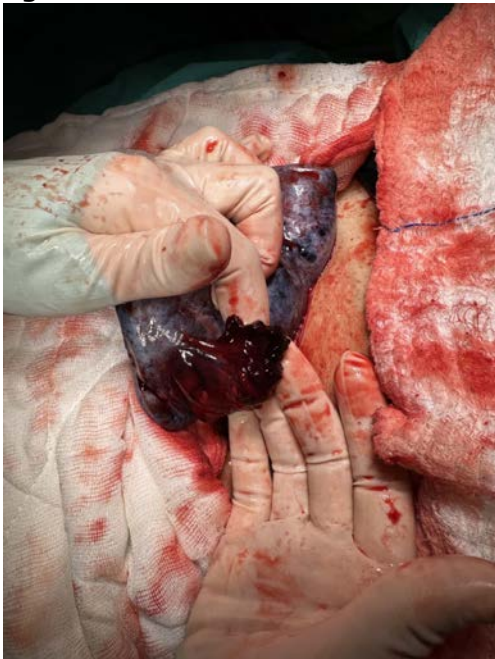Keywords: pregnant torsion, torsion, Ovarian torsion

figure 1



Torsioned ovaries can be saved, and preservation is recommended unless malignancy is suspected. Rarely, ovarian, or tubal necrosis is present. In our case, we performed a right salpingo-oophorectomy because we observed signs of infarct, and the patient had a history of lymphoma and ovarian torsion. In the light of this knowledge, it is of great importance to form a consensus on the time to intervene considering the week of pregnancy, and size of ovarian cysts.

figure 2



SS-67

V-Y advancement flap repair of a large defect after vulvectomy in a case of high-grade Vulvar Intraepithelial Neoplasia (VIN3)

Çağatayhan Öztürk, Uğur Fırat Ortaç
Department of Obstetrics and Gynecology, Ankara University Medical School

Objective: The increase in the diagnosis of VIN3 reflects higher awareness, increased diagnostic success and an increase in the absolute incidence of the disease. Classical VINs are more common and are associated with Human Papilloma virus (HPV). High-risk HPV types, especially HPV 16, are among the causes of high-grade VIN. The most common symptoms are itching, burning, pain and dysuria. It tends to be multifocal and diffuse in young patients. The clinical appearance varies depending on age and skin color as well as the localization of the lesion on the vulva and perianal area. Colposcopy is the currently accepted diagnostic evaluation tool, and pigmented lesions show skin-colored or wavy acetowhite areas when stained with 5% acetic acid. Biopsy should be used liberally. VINs tend to progress and up to 30% are associated with invasive cancer. The goal of treatment is symptom control and prevention of progression to invasive cancer. The wide age distribution and the extent of the disease require individualization of treatment for each patient. VIN lesions are best treated by local superficial excision (skinning). In patients with negative surgical margins, 90% cure is achieved, while this rate drops to 50% in patients with (+) surgical margins. Due to the elasticity of the vulvar skin, the defect can usually be closed primary.

Results: A 47-year-old female patient presented with itching, burning and discoloration of the vulvar skin in 2018. After the biopsy result was VIN3, the patient underwent vulvectomy, all macroscopic lesions were removed, surgical margins were positive and the patient was followed up. During the pandemic period, the patient did not attend the follow-up visits and presented to the clinic with widespread itching and discoloration in the vulvar and perianal region. VIN3 was detected after multiple biopsies and wide excision was planned. The cervix of the patient with HPV 16(+) was evaluated colposcopically. Preoperative colostomy was opened because the lesions extended to the anal canal. The lesions in the vulvar and perianal regions were extensively removed by entering the anal canal. The defects in the vulvar region were closed with primary closure and the defect in the perianal region was closed with a V-Y advancement flap.

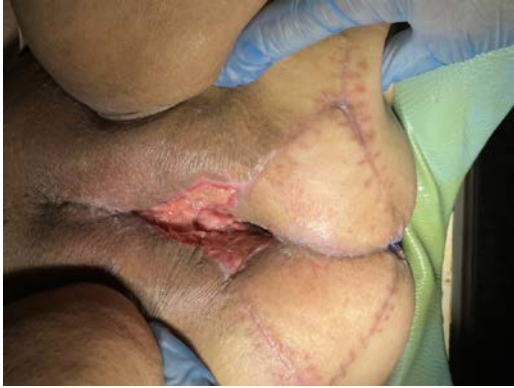Conclusion: CO2 laser cannot be used in large VIN cases due to high morbidity. In cases where skinning vulvectomy is performed, cutaneous flaps or full-

thickness skin grafts can be used if the defect is large. The V-Y advancement flap is a very useful flap that is frequently used in the repair of defects in the head and neck region. To ensure successful reconstruction, repair with tissue of similar histology, thickness and structure provides a more successful and acceptable reconstruction. For this purpose, defect repair with tissue extending either along the same aesthetic unit or along the adjacent unit is the most ideal.

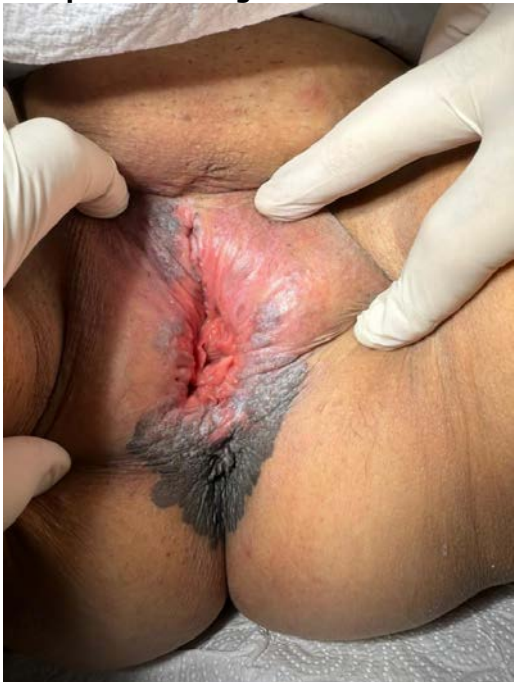Local flaps are often better than grafts or distant flaps in terms of aesthetic and functional results.

Keywords: vulvar intraepithelial neoplasia, vulvectomy, V-Y flip

Postoperative image



Preoperative image of the vulva



SS-68

OBSTETRIC and ONCOLOGIC OUTCOMES of SEX-CORD STROMAL TUMORS

Mehmet Tunc

Division of Reproductive Endocrinology and Infertility

OBJECTIVE: To investigate oncologic (such as disease-free, and overall survival) and obstetric outcomes of patients diagnosed with ovarian sex-cord stromal tumors OSST who underwent fertility-sparing surgery (FSS) in our center.

METHODS: This study evaluated patients who were diagnosed with OSST between February 2007 and June 2020. Calculations for survival and follow-up were made by September 2023. Patients who did not undergo FSS were excluded from the study.

The data of patients including age, marital status, menstrual patterns, surgery time, operation notes, histopathological subtype, chemotherapy administration, obstetric outcomes, and recurrence and survival status were obtained from hospital records and patient files. All pathological specimens were re-evaluated by an experienced gynecologic pathologist.

The chemotherapy regimen for OSTT has consisted of 3 courses of bleomycin, etoposide, and cisplatin or 6 courses of paclitaxel, and carboplatin. The decision for chemotherapy administration for patients was based on tumor stage and histological subtype and made by the institutional tumor board.

The obstetric outcome was evaluated by collecting data till the patient's last follow-up visit from the hospital records and patient files.

RESULTS: A total of 35 patients were included in this study. The median age of the patients was 29.0 years (range:12-44). The median follow-up time was 117.0 months (39-199).

The most common histological subtype was granulosa cell tumors (65.7%). The prominent subtype of granulosa cell tumors was adult type (54.3%).

Histologic, stage distribution, oncologic, and obstetric outcomes of the patients were given in table 1.

The 5-year disease-free and overall survival of the patients was 85.3 and 97.1%, respectively. There were no significant differences between the stage of the disease for disease-free and overall survival.

CONCLUSION: Ovarian sex-cord stromal tumors are very rare, and mostly seen in adolescent and young-aged patients. This study gives oncologic and obstetric



5. Jinekoloji ve Obstetrikte Tartışmalı Konular Kongresi

5-8 Ekim 2023 | Hilton Dalaman Sarıgerme

outcomes of this rare tumor of a single center with almost a 10-year follow-up time.

Keywords: Sex-Cord Stromal Tumor, Fertility-Sparing, Fertility-Preservation, Oncofertility

Demographic, Oncologic, and Obstetric Outcomes of the Patients

Age (n) - Granulosa o Adult type (19) o Juvenile type (4) - Sertoli-Leydig (8) Sex Cord Unclassified (4)	Median (Range) 31.0 (16-42) 19.0 (15-34) 20.50 (12-33) 24.5 (15-44)	P 0.061
Histology - Granulosa o Adult type o Juvenile type - Sertoli-Leydig - Sex Cord Unclassified	N (%) 23 (65.7) 19 (54.3) 4 (11.4) 8 (22.9) 4 (11.4)	
Stage - IA - IC1 - Locoregional (II-III)	N (%) 21 (60) 12 (34.3) 2 (5.7)	
Surgery - USO±Staging - Cystectomy±Staging	N (%) 29 (82.9) 6 (17.1)	
5 year DFS - IA - IC1 - Locoregional (II-III)	% 79.6 91.7 100	P 0.532
5y OAS - IA - IC1 - Locoregional (II-III)	% 94.1 91.7 100	P 0.851
Obstetric Outcomes	8 patients got pregnant with pregnancies 5 of 8 patients had at least 1 livebirth 6 livebirths 4 miscarriages 1 molar pregnancy	

Table 1. Demographic, Oncologic, and Obstetric Outcomes of the Patients

SS-70

Assessment of the impact of treatment process on clinical outcomes in uterine papillary serous carcinoma

Şefkat İlayda Embel¹, Nejat Özgül²

¹1. Hacettepe University Faculty of Medicine Department of Department of Obstetrics and Gynecology, Ankara, Turkey

²2. Hacettepe University Faculty of Medicine, Department of Obstetrics and Gynecology, Division of Gynecologic Oncology, Ankara, Turkey

OBJECTIVE: Endometrial cancer is the sixth most common cancer among women worldwide. The most common non-endometrioid histological type is serous endometrial cancer and accounts for 10% of the cases. It can be detected at an earlier stage at diagnosis than the endometrioid subtype but has a higher risk of recurrence. Prognosis of serous subtype is worse than the endometrioid subtype at the same stage. The most important feature is that the serous subtype is responsible for 40% of endometrial cancer related deaths. In this study, we aimed to define the changes in clinical outcomes of patients under our follow up with a diagnosis of serous endometrial cancer, based on their stages and pathological characteristics.

MATERIALS-METHODS: A cohort of 118 patients with uterine papillary serous carcinoma who were treated at Hacettepe University Hospital between 2001 and 2022 were retrospectively reviewed. The Kaplan-Meier method was used for survival analysis. Factors predictive of outcome were compared using the log-rank test and Cox regression analysis. Roc Curves were used to compare the performance of FIGO 2009 and 2023 stage systems.

RESULTS: The mean age at the time of diagnosis was 66,1 years (66,1±8,24). Whole of the patients were managed surgically and 78% were completely surgically staged. According to FIGO 2023; there were 10 patients with stage I, 41 with stage II, 28 with stage III and 39 with stage IV disease. The median follow-up was 30 months (range=1,6-219 months). The 5-year overall survival among all patients was 45,5%. 60,2% of patients were died at the end of the follow up period. There was no significant difference in overall survival based on performing lymphadenectomy (p=0,09) and performing omentectomy (p=0,79) during surgery. On the other hand; tumor size ≥3 cm (p=0,006), positive peritoneal cytology (p<0,001), tumors arising from polyp (p=0,02), positive lymphovascular space invasion (p<0,001), cervical involvement (p=0,003), depth of myometrial invasion (p=0,002) were associated with overall survival. Multivariate Cox analysis confirmed



5. Jinekoloji ve Obstetrikte Tartışmalı Konular Kongresi

5-8 Ekim 2023 | Hilton Dalaman Sarıgerme

that age ≥ 60 (HR=3,52 [95% CI: 1,17–10,57], $p=0,25$), elevated serum ca125 levels (HR=2,07 [95% CI: 1–4,3], $p=0,04$) and Stage III or IV disease according to FIGO 2023 (HR=1,18 [95% CI: 1,06–1,31], $p=0,002$) were the independent prognostic factors for overall survival. Whereas elevated serum ca125 levels (HR=2,42 [95% CI: 1,24–4,71], $p=0,009$) and Stage III or IV disease according to FIGO 2023 (HR=1,2 [95% CI: 1,09–1,31], $p<0,001$) were found to be independent prognostic factors for disease free survival.

CONCLUSION: Uterine papillary serous carcinoma is an aggressive variant of endometrial cancer and associated with low overall survival. In our patients, prognosis was independently determined by elevated serum ca125 levels and advanced FIGO stage at diagnosis. Also we detected performing omentectomy and lymphadenectomy doesn't have a positive effect on survival. In our patient group, the new FIGO staging was compared with the old FIGO staging, and we found that patients with serous endometrium cancer at stage I increased to stage II. However, in the roc curve analysis, we observed that the performances of both stagings were similar.

Keywords: surgical staging, uterine papillary serous carcinoma, survival

SS-71

The Role of MRI in Adnexal Torsion Diagnosis

Feyzanur Verim¹, Haticegöl Tuncer¹, Makbule Buse Çakmak¹, Fatma Caner Çabukoğlu¹, Derman Başaran¹, Deniz Akata²

¹Department of Obstetrics and Gynecology, Hacettepe University, Ankara, Turkey

²Department of Radiology, Hacettepe University, Ankara, Turkey

OBJECTIVE: This study aims to retrospectively evaluate the predictive value of MRI in the diagnosis of torsion in patients who underwent surgery with a preliminary diagnosis of torsion and were confirmed to have surgical adnexal torsion.

METHOD: Between the years 2013 and 2023, 75 patients who underwent surgery with a preliminary diagnosis of torsion in Hacettepe University were retrospectively screened. The outcomes of surgical intervention were compared with the torsion diagnoses from magnetic resonance imaging (MRI) evaluations conducted by the radiology department. Statistical data were analyzed using Chi-Square, and p-values were calculated.

RESULTS: It was observed that the average age of patients diagnosed with surgical torsion was 29.7. The

presenting complaints were abdominal pain, nausea, and vomiting in order of frequency. The nature of abdominal pain was described as continuous pain (29/42), colicky pain (11/42), and sharp pain (6/42). Right adnexal torsion was identified in 62.5% of patients (n:40). 64 patients were found to have adnexal torsion during the surgery. Among these patients, it was observed that 27 had undergone MRI with suspicion of torsion. The preliminary MRI reports of the conducted MRIs and the final results were evaluated separately in terms of intraoperative correlation. Among the 27 patients who underwent MRI with suspicion of torsion, torsion diagnosis was confirmed based on the preliminary MRI report for 25 patients. Out of these 25 patients, 19 received a surgical diagnosis of torsion (Positive Predictive Rate: 76%). In the final results of the 27 patients who underwent MRI with suspicion of torsion, compatible findings with torsion were observed in 23 patients. Among these 23 patients, 20 received a surgical diagnosis of torsion (Positive Predictive Rate: 87%). Out of the 20 patients who received a surgical diagnosis of torsion, all 20 were diagnosed with torsion through MRI (Sensitivity: 100%). Among the 7 patients who did not have a surgical diagnosis of torsion, MRI did not show torsion in 4 cases, while it was reported that torsion was observed in 3 cases (Specificity: 57%). ($p = <0.05$)

CONCLUSION: This study emphasizes the clinical importance of not missing the diagnosis, given the average age of torsion patients being 29 and the potential direct impact of delayed diagnosis on fertility loss and reduction. Although specificity is important in cases that can lead to fatal outcomes or organ loss, sensitivity should be prioritized in the diagnosis of such diseases. The study demonstrates that MRI has a significant role in predicting torsion diagnosis with a 100% sensitivity indicating its importance in torsion diagnosis. This study demonstrated that, despite the expense of MRI as a diagnostic method, MRI is an effective diagnostic tool that can be used on patients with clinically uncertain diagnoses.

Keywords: Adnexal Torsion, MRI, Detorsion

SS-72

A rare tumor case: Retroperitoneal Myxoid Liposarcoma

Volkan Karataşlı, Çağla Bahar Bülbül Hanedar
Department of Gynecology and Obstetrics, Balıkesir Atatürk City Hospital, Balıkesir, Turkey

INTRODUCTION: Retroperitoneal myxoid liposarcoma is a very rare soft tissue tumor.

In the literature, the number of cases seen in the retroperitoneal region that have reached very large sizes is low.



5. Jinekoloji ve Obstetrikte Tartışmalı Konular Kongresi

5-8 Ekim 2023 | Hilton Dalaman Sarıgerme

CASE: A sixty-four-year-old case (G 3 P 3, body mass index: 38.3 kg/m²) had pelvic pain and abdominal pain. She applied to the gynecological oncology outpatient clinic due to a mass. Patient's deep vein thrombosis had a history. There was no history of drug use or previous surgery in her medical history. It was learned that she had previously received treatment for bone tuberculosis. During the examination, the cervix could not be clearly observed due to mass compression. Pelvic ultrasonography reveals solid nodular lesions with heterogeneous internal structure. A mass lesion was observed. Abdominopelvic magnetic resonance imaging showed 110x95 mm heterogeneous dense tumor pushing the uterus anteriorly in the left lateral part of the pelvis. A giant solid mass lesion showing contrast enhancement was observed. The mass passed inferiorly to the left perianal canal. It was extending in the right direction and was causing significant dilatation by putting pressure on the left ureter. The patient underwent surgery via laparotomy. Retroperitoneal mass excision was performed. No residue was left. No postoperative complications occurred. In the pathology reports, the tumor was determined as myxoid liposarcoma. Total size was 22x15x10cm and contained a thin capsule. Hypercellular areas were common in the tumor and approximately 40% of the tumor contained a round cell component. There were focal areas of necrosis, and 15 mitoses were detected in 10 high power fields. Tumor differentiation score=2, mitosis score=2, necrosis score=1, round cell differentiation=3, Total score=8 and histological grade was calculated as 3. In immunohistochemical analysis, desmin negative, actin negative, CD34 positive in vascular endothelial cells, S100 positive, LCA positive in lymphocytes, PANCK negative, vimentin positive, ki-67 20% positive, HMB45 and MELAN A negative. No residual disease was detected in postoperative computed tomography and positron emission tomography. Due to the risk of recurrence, the patient was started on doxorubicin (120 mg). The patient refused treatment due to the development of Bell's palsy after four cures. At the 20th postoperative month, a 6.5x5 cm recurrence was detected on the left in the retroperitoneal area in the operation room. The patient did not want additional treatment or surgery. At the 54th month after the operation, clinical follow-up continues as he is asymptomatic with recurrent disease, 4.5x3 cm on the right and 7x6 cm on the left.

CONCLUSION: Myxoid liposarcoma is a very rare condition. Therefore, its clinical and prognostic significance has not been determined. Treatment by wide surgical excision is recommended, but adjuvant treatment options are unclear. Close clinical follow-up is recommended for patients due to the risk of recurrence.

Keywords: myxoid liposarcoma, retroperitoneum, sarcoma

SS-73

Comparison of the Performance of IOTA Simple Rules, Simple Rules risk assessment, and O-RADS in differentiating between benign and malignant adnexal lesions

Ece Ceylan Eng

Istanbul Bakirkoy Doctor Sadi Konuk Training and Research Hospital

OBJECTIVE: International Ovarian Tumor Analysis-Adnex Models (IOTA SR and SRRisk and Ovarian-Adnexal Reporting and Data System (O-RADS) have been developed for the diagnostic accuracy of adnexal masses in the preoperative period. This study aimed to evaluate O-RADS and IOTA Model scores of patients who had surgery for an adnexal mass and diagnosed in our hospital and interpret the roles of scores in management. **MATERIALS-METHODS:** Our study was carried out with patients who were operated on in our hospital between June 2022 and December 2022 with a preliminary diagnosis of adnexal mass. Preoperative ultrasonography imaging of the patients, morphological definitions of adnexal masses and vascularization patterns obtained by Doppler ultrasonography were evaluated by IOTA SR, Simple rules risk calculator and O-RADS Scores., preoperative malignancy risk will be calculated and the pathology report obtained with the histopathological diagnosis of the post-surgical material is accepted as the gold standard, and the effectiveness of the IOTA SR, SRRisk and O-RADS criteria in the differential diagnosis of preop; Sensitivity, specificity, positive predictive value and negative predictive values were calculated and compared with each other. SPSS version 25.0 program was used in the analysis of statistical data. **RESULTS:** 127 patients were included in the study. Among the patients included in the study, 98 (77.17%) were diagnosed as benign and 29 (22.83%) were diagnosed as malignant. For comparison between groups, $\geq 10\%$ malignancy risk was accepted as the cut-off value. When the cut-off $\geq 10\%$ was taken for the IOTA SRR, 87.76% Sensitivity, 86.21% Specificity, 95.56% PPD and 67.57% NPD were obtained. When O-RADS category 2-3 Benign, 4-5 Malignant were taken, 89.66% Sensitivity, 78.57% Specificity, 55.32% PPD and 96.25% NPD were obtained. **CONCLUSION:** According to our study, while the IOTA SRRisk model has similar sensitivity to the O-RADS risk classification system in malignancy risk assessment; specificity, PPD and NPD are significantly higher in the IOTA SRRisk model. When these 3 models are compared, it can be recommended to use the IOTA SRRisk model in daily practice in the prediction of preoperative malignancy of adnexal masses due to its numerical risk score, its applicability by ultrasonographers of all levels, that is, it does not require the opinion of an expert ultrasonographer, and it has the highest diagnostic accuracy values.

Keywords: adnexal mass, IOTA, O-RADS, ovarian neoplasms, ultrasonography

VIDEO BİLDİRİLER



www.obstetrikjinekolojitarismalikonular.org



5. Jinekoloji ve Obstetrikte Tartışmalı Konular Kongresi

5-8 Ekim 2023 | Hilton Dalaman Sarıgerme

VS-01

Video Case Report: Single-Port Laparoscopic Surgery for Huge Adnexal Mass (> 30cm) using the GelPOINT Device

Kemal Gungorduk, Berican Şahin Uyar
Division of Gynecologic Oncology, Department of Obstetrics and Gynecology, Faculty of Medicine, Muğla Sıtkı Kocman University, Mugla, Turkey

AIM: We report the case of a young woman with a large abdominal mass that was successfully management using a single-port laparoscopic approach.

CASE: 34-year-old woman G2P2L2 with a 4-month history of cyclical abdominal pain, constipation and an abdominal swelling. Computed tomography of the pelvis revealed a left ovarian cyst 30.2x23.5 cm in size with no solid elements. CA 125 was 15,3 u/l, and all other tumour markers were negative.

Keywords: Single-port laparoscopic surgery, ovarian mass, video case report

VS-02

Single-Port Laparoscopic Surgery for Ovarian Fibrothecoma

Kemal Gungorduk, Berican Şahin Uyar
Division of Gynecologic Oncology, Department of Obstetrics and Gynecology, Faculty of Medicine, Muğla Sıtkı Kocman University, Mugla, Turkey

Ovarian fibrothecoma are a mostly benign and profoundly rare type of gonadal stromal cell tumor. It is a rare gynecological pathology. A 39-year-old female who presented complaining only of a slow progressive increase in the abdominal contour associated with vague abdominal pain. Preoperative radiological imaging revealed solid ovarian mass. CA 125 was 11 U/L, and all other tumour markers were negative. The patient underwent left salpingo-oophorectomy with benign frozen section results.

Keywords: Ovarian fibrothecoma, Single-Port Laparoscopic Surgery, Video case report.

VS-03

Real-Time Visualization of Ureters Using Indocyanine Green During Laparoscopic Hysterectomy

Emre Genç, Seda Şahin Aker
Department of Gynecologic Oncology, Kayseri City Hospital, Turkey

Ureteral damage is one of the serious complications in laparoscopic surgeries. We are able to take advantage of next-generation technologies to prevent ureteral damage. In this case, we present a 48-year-old female patient with a previous history of ileus, with left ureteral ICG injection. Firstly, cystoscopic-guided intraureteral ICG injected with a 6-Fr ureteral catheter. The fluorescence of ureters was visualized in the overlay mode of the camera system (Stryker 4K), localizing the ureter in real time. This is a safe and feasible method that provides real-time ureteral demarcation. This method can make ureteral visualization safer in complex laparoscopic pelvic surgeries.

Keywords: indocyanine green, real-time visualization, ureteral identification

VS-04

Step by step sentinel lymph node concept in endometrium cancer

Koray Kaya¹, Emre Genç¹, Seda Şahin Aker²

¹Gynecology and Obstetrics, Kayseri City Education and Training Hospital, Kayseri, Turkey

²Department of Gynecologic Oncology, Kayseri City Education and Training Hospital, Kayseri, Turkey

Sentinel lymph node mapping is getting a standard method use in endometrial cancer, it is also included in the NCCN guideline. A 62-year-old patient (G3P3) with grade 1 endometrioid endometrium cancer, with a height of 165 cm and a weight of 88 kg (BMI: 32.3) admitted to gynecologic oncology clinic. PET-CT showed only uterus involvement. Myometrial invasion was evaluated under 1/2 in ultrasonography. After injection 2 ml ICG to the 3-9 position of cervix (total 4 ml) retroperitoneal dissection started. Pelvic area observed and the lymphatic chain followed with Stryker 4K imaging system. Bilateral sentinel lymph node detected in the obturator area and excised. In the frozen section myometrial invasion observed under 1/2 and in the final pathology sentinel lymph nodes evaluated with ultrastaging and the result was negative and stage was 1A. Patient didn't receive any treatment due to the final pathology.

Keywords: sentinel lymph node, endometrial carcinom, fluorescence imaging



5. Jinekoloji ve Obstetrikte Tartışmalı Konular Kongresi

5-8 Ekim 2023 | Hilton Dalaman Sarıgerme

VS-05

Excision of type 2 myoma with a hysteroscopic morcellator

BÜŞRA DEMİR ÇENDEK¹, Seda Şahin Aker²

¹Department of Obstetrics and Gynecology, Health Sciences University Etlik Zübeyde Hanım Maternity, Teaching and Research Hospital

²Department of Gynecologic Oncology, Kayseri City Hospital, Turkey

Hysteroscopic morcellation for intrauterine pathological lesions is significantly faster than conventional loop resectoscope. In this video presentation we demonstrate two patients with type 2 myoma. First patient is 28 year-old suffers from infertility and have 3 cm type 2 myoma. The second patient is 34 years old, she has 3-4 type 2 fibroids and her main complaint is menorrhagia. We used the TRUCLEAR system. The TRUCLEAR (Smith and Nephew, Andover MA, USA) technique, which is based on an instrument that consists of a set of two metal hollow rigid tubes that fit into each other. The 4.0-mm morcellator is introduced in the uterine cavity through a straight-forward working-channel of a continuous flow 8-9 mm rigid hysteroscope. Generally dominated by decreasing outer diameter without losing the quality of the image. Newer hysteroscopes provide separate in and outflow channels. With this technology, operations are faster, less traumatic, have lower probability of hyponatremia. Another advantage is the availability of newer fluid-management systems that are more reliable and precise in measuring in- and outflow fluids, and therefore improve patient safety.

Keywords: hysteroscopy, morcellator, endoscopy

VS-06

First step into the bladder: uterovesical fistula in 23 weeks of pregnancy

Mehmet Faruk Köse¹, Mehmet Aytaç Yüksel³, Mustafa Deveci²

¹Acıbadem Mehmet Ali Aydınlar Üniversitesi, Atakent Hastanesi, Jinekolojik Onkoloji AD, İstanbul, Turkey

²Acıbadem Atakent Hastanesi, Kadın Hastalıkları ve Doğum Kliniği, İstanbul, Turkey

³Acıbadem Atakent Hastanesi, Kadın Hastalıkları ve Doğum Kliniği, Perinatoloji AD, İstanbul, Turkey

AIM: we aimed to present a case of uterovesical fistula with 23 weeks of pregnancy.

METHOD: We detected the fistula by noticing that right foot of the fetus is inside vesical cavity with intact amniotic sac. The fetus was not viable, so we decided to restore the fistula and put the fetus and amniotic sac into its own habitat. We recorded the surgery and aimed to present the surgical steps.

RESULT: Gynaecology and urology teams performed the surgery without fetal or maternal complication, and the pregnancy continued until 36 weeks. We performed routine c-section without any complication and delivered 2340gr healthy boy with 8-9 APGAR score.

DISCUSSION: Uterovesical fistula is very rare complication of repeated previous c-section surgeries in young woman. If there is pregnancy in diagnosis time, it is a challenge to manage the fetal and maternal health. In this case, we managed to keep the fetus inside the uterus 13 more weeks after the fistula surgery.

CONCLUSION: In written English medical literature, we could not find a reported case in which the pregnancy continued, so we aimed to show this unique case and the surgical steps of restoring the organs and fetus to its own locations.

Keywords: uterovesical fistula, vesicouterine fistula, pregnancy, fistula

VS-07

En-block resection of the lower abdominal wall for recurrent endometrial cancer

Hasan Volkan Ege¹, Nejat Ozgul¹, Murat Gultekin¹, Gökhan Sert², Derman Basaran¹

¹Department of Obstetrics and Gynaecology, Division of Gynaecologic Oncology, Hacettepe University, Ankara, Turkey

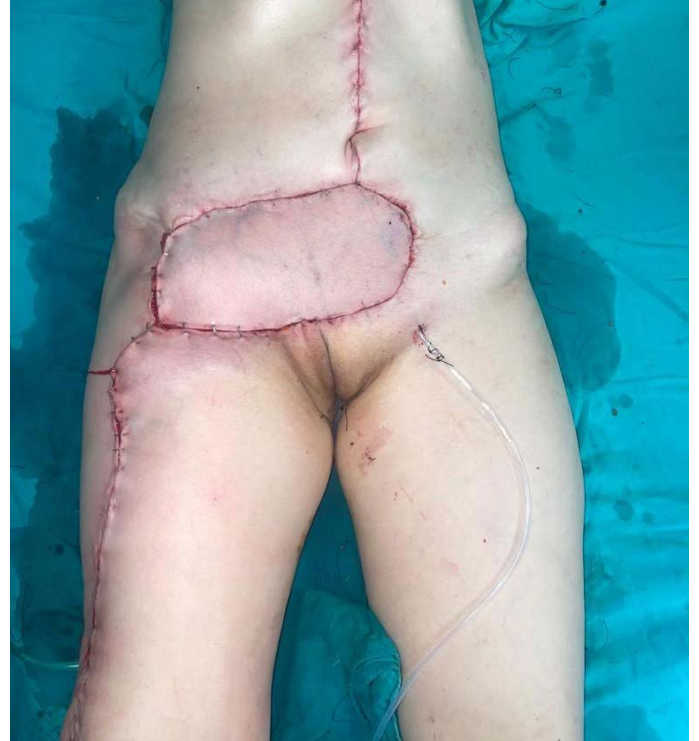²Department of Plastic Reconstructive and Aesthetic Surgery, Hacettepe University, Ankara, Turkey

The typical metastatic sites for endometrial cancer are the pelvic and para-aortic lymph nodes, as well as the vagina, peritoneum, and lungs. Abdominal wall metastases are quite rare. Here we present an en-block resection of lower abdominal wall in a patient with recurrent endometrial cancer and closure of the massive defect using a pedicled rectus femoris flap.

Case Presentation: A 52-year-old patient was diagnosed with EC in 2011 and underwent a total abdominal hysterectomy, bilateral salpingo-oophorectomy, and lymph node dissection. Adjuvant chemotherapy was administered for the patient classified as Stage 3A according to FIGO (2009) criteria. Seven years following her initial treatment, the patient had a groin metastasis in 2018 and underwent local excision followed by radiotherapy. Patient recurred in the same location and underwent three additional local excision procedures. In June 2023, the patient was evaluated for suspected multiple metastases in the anterior abdominal wall. A comprehensive excision of the anterior abdominal wall, including metastatic areas, was planned in conjunction with plastic surgery. The lower abdominal wall including the lateral aspect of the right inguinal ligament was excised en-block. Subsequently, the fascial defect in the abdomen was repaired with mesh by the plastic surgery team. A lateral incision on the right thigh was used to harvest a pedicled anterolateral thigh flap. A skin island matching the size of the skin defect on the anterior abdominal wall was designed and the flap was raised on a single septocutaneous perforator including only the skin, subcutaneous fat and deep fascia preserving the thigh musculature. The flap was passed under the rectus femoris muscle for better arc of rotation (Image-1). The perfusion of the flap was confirmed with ICG assistance. The postoperative period was managed in collaboration with the plastic surgery team. An abdominal corset was used for abdominal wall support. The drain placed in the flap's cavity was removed on the 19th day after surgery, and the patient was discharged.

Keywords: Abdominal wall metastases, Flap, Recurrent endometrial cancer

Figure-1: Abdomen wall after surgery



VS-08

Laparoscopic Ovarian Transposition Before Pelvic Radiotherapy

Betül Ahat, Merve Savaş, Rıza Dur, Dağıstan Tolga Ariöz

Obstetrics and Gynecology, Afyonkarahisar University of Health Sciences Faculty of Medicine, Afyonkarahisar, Turkey

Introduction and PURPOSE: In this case report, we wanted to present our case of laparoscopic ovarian transposition performed to avoid the devastating effects of pelvic radiation therapy.

METHOD: Radiotherapy was planned for a 15-year-old patient diagnosed with L5-S1 ependymoma grade2 and referred to us. In the transabdominal ultrasound performed, the uterus antevert anteflex endometrium double wall thickness was 5 mm, bilateral ovaries were observed as normofollicular. The patient was admitted to the service by planning a laparoscopic lateral transposition of the bilateral ovaries operation.

FINDINGS: The operation was performed with 10 mm main trocar inserted from the umbilicus and 5 mm auxiliary trocar inserted from the bilateral lower quadrants. From the main trocar, the camera was inserted into the abdomen and the uterus, bilateral tuba, ovaries and ureters were identified. First, the peritoneum on



5. Jinekoloji ve Obstetrikte Tartışmalı Konular Kongresi

5-8 Ekim 2023 | Hilton Dalaman Sarıgerme

the left infundilopelvic ligament was opened, then the utero-ovarian ligament was transected by coagulation, and then the infundibulopelvic ligament was liberalized by dissecting the mesosalpinx and mesovarium. Subsequently, the right ovary was liberalized by the same method. After that, the left ovary was fixed to the disastar with 1 no1 vicril and 1 no 1 prolene suture at a distance of 4 cm from the iliac crest, and the right ovary was fixed to the disastar with 1 no 1 vicryl suture. A sign was placed with 2-3 steps in the area where both ovaries were fixed. The operation lasted 90 minutes, the bleeding was up to 50 cc. Final checks were made and the operation was terminated.

Discussion and CONCLUSION: The purpose of ovarian transposition is to protect the ovaries from the destructive effect of radiation and thus maintain endocrine function and fertility. Most of the data on reproductive function after ovarian transposition are based on case reports or small case series. The complication rates of laparoscopic ovarian transposition are low and ovarian function is preserved in most patients.

Keywords: Ependymoma, fertility, ovary, radiation therapy, surgery

VS-09

Treating stress urinary incontinence with laparoscopic burch colposuspense

Elif Yıldız, Esra Nazlı Döktür Efeoğlu, Süleyman Salman Health Sciences University, Gaziosmanpaşa Training and Research Hospital, Department of Gynecology and Obstetrics

METHODS: A 35-year-old patient who had 3 normal births applied to us with the complaint of urinary incontinence when coughing, sneezing and lifting heavy weights affecting his social life, which has increased in the last 6 months. When questioned, the patient, who stated that her delivery was difficult, had no urge complaints. urine culture results performed one week ago in an external center were seen, and there was no urinary tract infection. The patient was taken to the lithotomy table for examination.

Spontaneous or valsava cystocele or other pelvic organ prolapse was not observed in the examination. When she was asked to cough with a full bladder, involuntary urine leakage was observed and the stress test was recorded as positive. After micturition, the residual urine volume of the patient was measured as approximately 35 cc. The patient was diagnosed with isolated stress incontinence and the decision to operate was made. Laparoscopic burch surgery was planned for the patient in order to protect the patient from possible complications of mesh.

Laparoscopic surgery was started in the dorsal lithotomy position under general anesthesia. From the anterior abdominal wall, at the intersection of the medial umbilical ligaments, the retrius space was entered with the help of ligasure. Cooper's ligaments were exposed in front of the pubis bone. The bladder was inflated 260 cc with methylene blue. With the help of a foley catheter in the bladder, the periurethral area was exposed by manipulation from the vagina

RESULTS: The patient's stress incontinence complaint had completely resolved in the next day's follow-up. After 25 cc of residual urine was detected on ultrasound, the patient was extubated. The patient was called for control in the 1st week, 1st month and 6th month postoperatively. There were no early or late complications in the patient who did not have any complaints of incontinence.

CONCLUSION: Laparoscopic Burch surgery provides not only good anatomical but also good functional results.

It can be done without opening the abdomen, a more physiological and more advantageous anatomical improvement is achieved because no foreign body such as mesh is used, and it is minimally invasive. Because of this, surgeons may prefer Burch surgery.

Keywords: stress urinary incontinence, laparoscopic, burch colposuspense

VS-10

Laparoscopic Hysterectomy Step by Step for Adnexial Mass

güner yaman, Seda Şahin Aker
Department of Gynecologic Oncology, Kayseri City Hospital, Kayseri, Turkey

A 42-year-old patient applied to the outpatient clinic with complaints of constipation and bloating. Pelvic ultrasonography revealed an approximately 7 cm solid echo mass in the left adnexal area. The imaging showed an appearance consistent with a sex cord stromal tumor, and tumor markers were negative. Laparoscopic hysterectomy, bilateral salpingo-oophorectomy, mass excision and frozen section were planned for the patient. The uterus and ovaries were removed from the vagina laparoscopically. The adnexal mass was excised with the help of an endobag without rupturing and was sent to frozen section. The surgery was terminated when the frozen section revealed theoma.

Keywords: laparoscopic, hysterectomy, adnexal mass excision



5. Jinekoloji ve Obstetrikte Tartışmalı Konular Kongresi

5-8 Ekim 2023 | Hilton Dalaman Sarıgerme

VS-11

Laparoscopic Myomectomy with Bag Morcellation

Ayşe Şahin, Seda Şahin Aker
Department of Gynecologic Oncology, Kayseri City Hospital, Kayseri, Turkey

FDA has restricted the use of Morcellators due to the risk of uterine sarcoma. Morcellation within the bag has gained importance. In this video presentation, we will present you a case of laparoscopic myomectomy and morcellation in the bag. A 36-year-old patient applied to the outpatient clinic with complaints of persistent abdominal pain and bloating. Pelvic ultrasonography showed an appearance consistent with a leiomyoma of approximately 12 cm in size originating from the anterior uterine wall. The patient was planned for laparoscopic myomectomy. After laparoscopic myoma excision, the myoma was removed with using a morcellator in the bag through the trocar entry area.

Keywords: laparoscopy, myomectomy, bag morcellation

VS-12

Definitive treatment for deep infiltrating endometriosis; a surgical video.

Muhterem Melis Cantürk
Obstetrics and Gynecology Department, Unye State Hospital

OBJECTIVES: The aim of this surgical video is to demonstrate definitive treatment of a patient who was operated for myoma uteri and deep infiltrating endometriosis. 48 years old patient had no complaints other than pelvic pressure. At the end of 5 years of follow up, the patient asked for a definitive treatment.

METHODS: Laparoscopic hysterectomy with bilateral salpingectomy was planned initially. During the surgery, bilateral dense adhesions were seen on both ovarian fossa. Sigmoid colon was densely adhered to the uterus. Pararectal spaces were developed. Ureter and uterine arteries were visualized on both sides. A rectal probe was placed to mobilize the sigmoid colon and facilitate the adhesiolysis. Sharp and blunt dissection were performed with laparoscopic bipolar and scissor. Adhesiolysis was performed until pararectal septum. At the end of adhesiolysis, laparoscopic hysterectomy with bilateral salpingo-oophorectomy was performed.

RESULTS: No postoperative complication was recorded.

CONCLUSION: Definitive treatment can be performed for deep infiltrating endometriosis in women who completed childbearing age. A surgical approach in favor of less aggressive surgery can be adopted for asymptomatic patients.

References:

1. Darwish B, Roman H. Surgical treatment of deep infiltrating rectal endometriosis: in favor of less aggressive surgery. Am J Obstet Gynecol. 2016 Aug;215(2).

Keywords: laparoscopic hysterectomy, deep infiltrating endometriosis, definitive treatment

VS-13

Laparoscopy in chronic pelvic pain; excision of sacrouterine ligament endometriotic nodules

Gözde Unsal¹, Mehmet Ceyhan², Özgür Takmaz¹, Mete GUNGÖR¹

¹Department of Obstetric and Gynecology, Acibadem MAA University, Istanbul, Turkey

²Department of Obstetric and Gynecology, Acibadem Maslak Hospital, Istanbul, Turkey

OBJECTIVE: The objective of this study is to demonstrate the surgical steps involved in excising sacrouterine ligament endometriotic nodules within the context of deep infiltrating endometriosis, which is characterized by chronic pelvic pain.

Design: Step-by-step video demonstration of the technique.

RESULTS: The patient was a 26-year-old woman with a history of constipation, dyspareunia, and chronic pelvic pain unresponsive to hormonal therapies. A preoperative examination revealed a sacrouterine endometriotic nodule measuring 12 mm, and preoperative ultrasonography indicated a 50mm ovarian cyst on the right side. A laparoscopy was performed. First the excision of the ovarian cyst on the right side was performed, followed by the excision of the sacrouterine endometriotic nodule. Both the endometriotic nodule and ovarian cyst were removed using an endobag. The overall operative time was 45 minutes, and no intraoperative complications occurred. A complete excision of endometriosis was achieved with an estimated blood loss of 10 mL. An intra-abdominal drain was not placed, and the urinary catheter was



5. Jinekoloji ve Obstetrikte Tartışmalı Konular Kongresi

5-8 Ekim 2023 | Hilton Dalaman Sarıgerme

removed at the end of the surgery. The patient was discharged two days after the surgery and did not experience postoperative complications.

CONCLUSIONS: Advanced laparoscopic surgical skills are required to perform effective and safe excision of sacrouterine ligament endometriotic nodules. Adequate preoperative evaluation is of utmost importance for appropriately planning the treatment strategy against endometriosis nodules in cases of chronic pelvic pain.

Keywords: Endometriosis, Laparoscopy, Surgery.

POSTER BİLDİRİLER



www.obstetrikjinekolojitarτισmalikonular.org

PS-01

A case report: Extrapelvic endometriosis presenting as a vulvar mass in a reproductive woman

Ceren Çebi¹, Oğuzhan Kuru²

¹Department of Gynecology and Obstetrics, Istanbul University-Cerrahpaşa, Istanbul, Turkey

²Department of Gynecology and Obstetrics, Division of Gynecological Oncology, Istanbul University-Cerrahpaşa, Istanbul, Turkey

INTRODUCTION: Endometriosis is a chronic, recurrent, progressive, inflammatory and estrogen-dependent disease characterized by the localization of endometrial gland tissue outside the uterine cavity. It is seen in 10% of women in reproductive age. Endometriosis is frequently seen in the ovaries, pelvic peritoneum, uterosacral ligament, and broad ligament. Extrapelvic endometriosis is a very rare condition. In 12% of endometriosis patients, endometriosis foci can be found in the extrapelvic area. Primary vulvar endometriosis is a very rare condition. Studies in the literature reported that there were few cases of primary vulvar endometriosis.

AIM: The aim of this poster is to present a case of primary vulvar endometriosis who was operated in our clinic.

FINDINGS: A 46-year-old female patient presented with swelling in the vulva with increasing pain during menstruation. No significant feature was found in the patient's anamnesis. She had no previous pregnancy. On physical examination and ultrasonography, a 7-8 cm firm, semi-fixed, semisolid mass was observed starting from the right labium majus and extending to the right inguinal region and mons pubis. The skin over the mass was observed as normal. Gross lymph nodes were not detected in both inguinal canals and lymphatic tracts. No signs of endometriosis were observed in the endopelvic area. No pathological blood flow was observed in the mass in ultrasonography. Epithelial tumors of the vulva, soft tissue tumors, neuroectodermal tumors were considered in the differential diagnosis.

In the contrast-enhanced pelvic MRI of the patient, hypointense T1W and T2W hypointense, contrast-enhancing, mild diffusion-restricting lesion of approximately 50*52*31 mm was observed under the skin in the right half of the vulva.

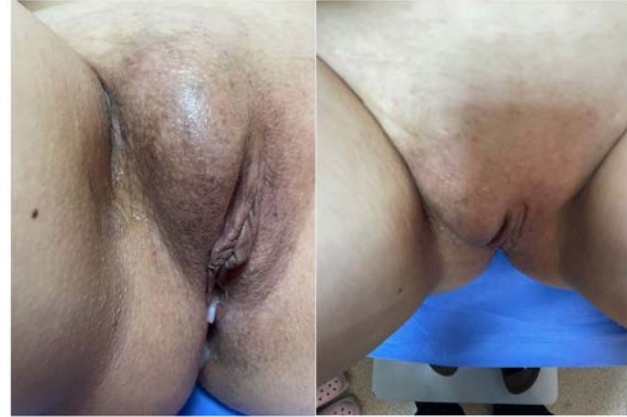There were no signs of pelvic endometriosis.

METHOD: The patient was operated on October 15, 2021 with these findings. The mass was resected from the vulva with a 0.5 cm surgical margin under general anesthesia.

CONCLUSION: Perioperative frozen section and final pathology resulted as endometriosis. The patient, who did not develop postoperative complications, was discharged on October 25, 2021, taking Dienogest 2 mg once a day. In the postoperative follow-up of the patient, dienogest 2 mg was given for 6 months. In the evaluations performed 6 months and 12 months later, no finding suggesting the recurrence of the disease was detected.

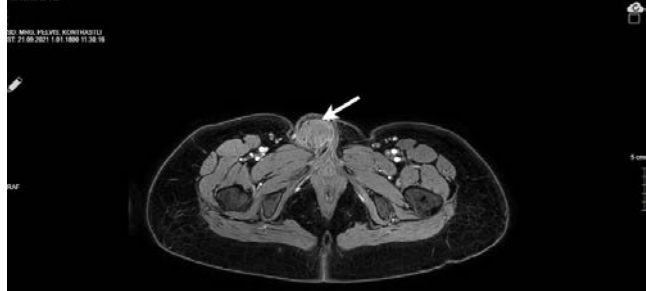Keywords: endometriosis, extrapelvic, vulvar mass

Figure 1



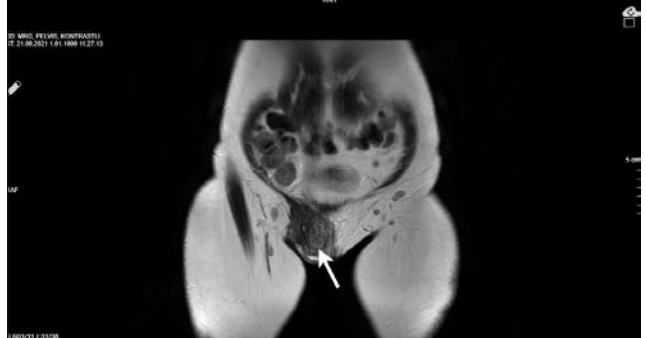Semi-solid 7-8 cm sized tumor of the right labium majus

Figure 2



MRI image of vulvar mass from transverse plane

Figure 3



MRI image of vulvar mass from coronal plane

PS-02

Laparoscopic Management of Complications in Gynecologic Laparoscopic Procedures

İsin Erdogan¹, Abdullah Serdar Acikgoz¹, Nilgun Çolakoglu², Abdullah Tuten¹

¹Department of Gynecology and Obstetrics, Istanbul University-Cerrahpaşa, Cerrahpaşa Medical Faculty, Istanbul, Turkey

²Department of Anesthesiology and Reanimation, Istanbul University-Cerrahpaşa, Cerrahpaşa Medical Faculty, Istanbul, Turkey

INTRODUCTION: Laparoscopic gynecological surgery is generally known for its low complication rates, with complications occurring in 0.2% to 18% of cases. These complications can occur due to previous intra-abdominal surgeries, procedure complexity, patient comorbidities and surgeon expertise. Most complications occur during intra-abdominal access and may increase in the presence of risk factors.

Complications occurring during laparoscopy include a wide range. Vascular injuries, intestinal injuries, urinary tract injuries, nerve injuries, surgical site complications (surgical site infection, port/extraction site hernia, port site metastasis and peripheral nerve injury) and pneumoperitoneum-related complications (subcutaneous/mediastinal emphysema, pneumothorax, cardiac arrhythmia, carbon dioxide retention, postoperative shoulder pain and gas embolism) are among them.

Vascular injuries, including arterial and venous injuries, occur approximately between 0.1 and 6.4 per 1000 laparoscopic procedures. The right iliac arteries and veins are the most commonly affected due to their close location to the surgical entry site. Such injuries have a high mortality rate, making swift recognition and expert intervention necessary to minimize blood loss. Although less common, bowel injuries are also a significant concern, contributing to a notable percentage of postoperative mortality. Injuries to the gastrointestinal tract occur in 0.03% to 0.65% of cases and can happen during both the access and dissection phases; small bowel injuries are more prevalent during access. Timely diagnosis is crucial, as delayed diagnosis can lead to necrosis and perforation. Injury prevention strategies involve meticulous technique, awareness of anatomical structures and proper instrument usage. In the case of vascular injuries, immediate involvement of vascular specialists is essential, with measures like direct pressure application and rapid abdominal opening used to control bleeding. Minor vascular bleeding can be managed through techniques like coagulation, compression and suturing. Intestinal injuries occurring during dissection

require identification and repair, and resection should be performed when necessary.

Case Reports

Case 1. A 49-year-old patient operated by laparoscopic hysterectomy, bilateral salpingo-oophorectomy and pelvic lymphadenectomy for endometrial cancer. During the dissection of loose tissues to access lymph nodes near the hypogastric artery, a ureteral injury about 2 cm in diameter occurred. First the affected part of the ureter was rapidly resected, followed by mucosa-to-mucosa anastomosis over a ureteral stent with absorbable sutures.

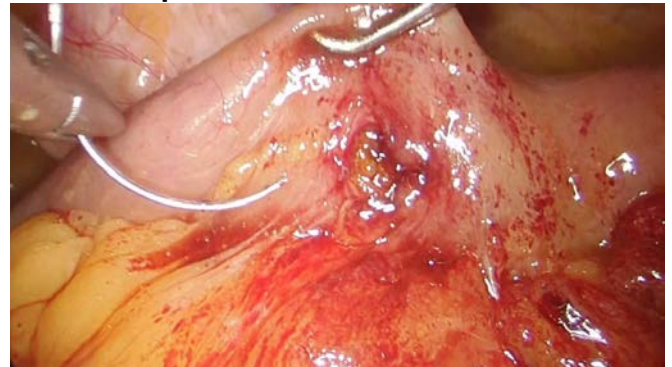Case 2. A 70-year-old patient, underwent hysterectomy previously, operated by laparoscopic sacrocolpopexy with mesh for vaginal prolapse. A superficial serosal injury of the small intestine occurred while retracting towards the back for better exploration. The injury was repaired through suturing.

Case 3. A 31-year-old patient having medical treatment-resistant dysmenorrhea and bilateral cystic ovarian masses appeared like benign lesions operated by laparoscopic cystectomy. During the procedure, as the laparoscopic needle was being inserted to hang and manipulate the right ovary, a branch of the right inferior epigastric vessel was accidentally damaged. The bleeding was successfully controlled by using laparoscopic transfixing suture technique.

DISCUSSION: Despite its low complication rate, laparoscopic gynecological surgery poses significant risks such as vascular and bowel injuries. Understanding the risk factors, early recognition and immediate intervention by experienced professionals are crucial for minimizing the impact of these complications and ensuring patient safety.

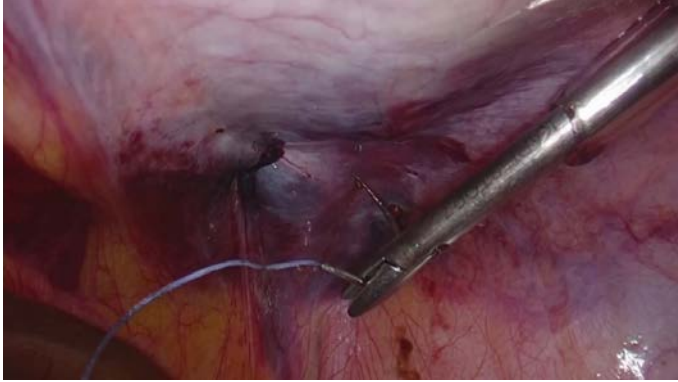
Keywords: Complications, Gynecological laparoscopy, Management, Risk Factors

Bowel Complication



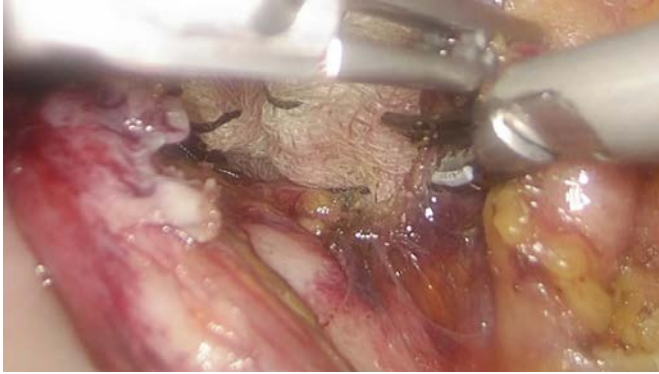Case 2

Branch of Inferior Epigastric Artery Complication



Case 3

Ureter Complication



Case 1

PS-03

Intrauterine CMV Infection: An Early Third Trimester Pregnancy With Fetal Intracranial Lesions

Dogu Kucuksuleymanoglu, Betul Akkus, Isin Erdogan, Abdullah Tuten, Riza Madazli
Department of Gynecology and Obstetrics, Istanbul University-Cerrahpaşa, Cerrahpaşa Medical Faculty, Istanbul, Turkey

INTRODUCTION: CMV is a DNA herpesvirus which can cause a lifelong infection due to its biological properties of latency and reactivation. CMV spread occurs via human-to-human contact with body fluids such as blood, saliva, genital secretion etc. The two main causes of CMV infection in pregnant women are sexual transmission and contact with young children. Transmission of the virus from an infected mother to a child can occur in utero, intrapartum or during breastfeeding (vertical transmission). Congenital CMV can cause sensorineural hearing loss, ventriculomegaly, intracranial calcifications, neurodevelopmental disabilities and growth failure. The risk of vertical

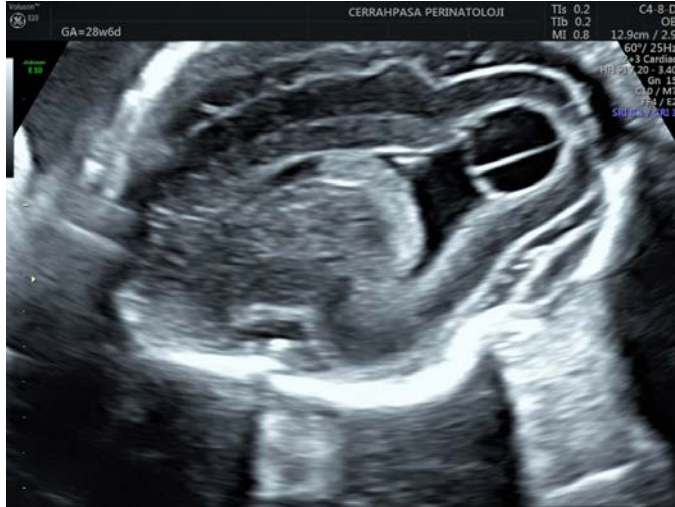transmission decreases with advancing gestation but the severity of sequelae increases as the gestation progresses. This report aims to present a fetus with intrauterine CMV infection consulted to the perinatology clinic in the 28th gestational week due to ventriculomegaly.

CASE: The 26-year-old patient with a prior healthy intrauterine pregnancy resulting with vaginal delivery was referred to our center for 2nd trimester detailed sonography evaluation upon detection of ventriculomegaly. She was 28w+4d pregnant according to her LMP. She had a history of rheumatoid arthritis and usage of certolizumab 200mg until the 20th GW. Her 1st trimester screening test was reported as low risk for aneuploidy and amniocentesis showed normal karyotype analysis. In her 2nd trimester sonographic assessment bilateral lateral ventricles were measured below 10mm. Microcephaly was detected. Multiple intraventricular hyperechogenic structures and intracranial cystic structures above the occipital part of the left lateral horn and vermis were observed. Cavum septum pellucidum could not be evaluated. Sylvian fissure was discordant with gestational age. Conus medullaris was extending to the sacral region. Fetal biometric parameters including EFW were all measured below the 1st percentile except for FL, which was measured in the 9th percentile. CMV IgM/CMV IgG antibody tests were ordered. In the second examination performed in late 29th GW, both CMV IgM/CMV IgG antibodies were positive. A dilated 4th ventricle (8.7mm), hyperechogenic cystic structures in the cerebellum, hyperechogenic parenchymal foci located in the vicinity of the frontal horn of right lateral ventricle were observed. The brainstem and pons appeared flattened. Amniocentesis and fetal blood sampling was performed. The pregnancy was terminated upon the request of the family. The karyotype analysis of amniocentesis material showed no quantitative or gross structural anomaly. Fetal blood had tested positive for CMV IgM.

DISCUSSION: In patients with CMV IgM positive after serological screening, IgG avidity testing should be performed. Definitive diagnosis of fetal infection should be diagnosed by analysis of amniotic fluid. Thus, the result of amniocentesis may be delayed, the findings should be supported by ultrasound and MRI. Cranial abnormalities as ultrasound findings (especially ventriculomegaly, periventricular echogenicity, echogenic intraparenchymal foci) is supportive for congenital infections. The combined use of ultrasound and fetal MRI in the third trimester has 95% sensitivity in identifying central nervous system-related lesions in a fetus known to be infected with CMV.

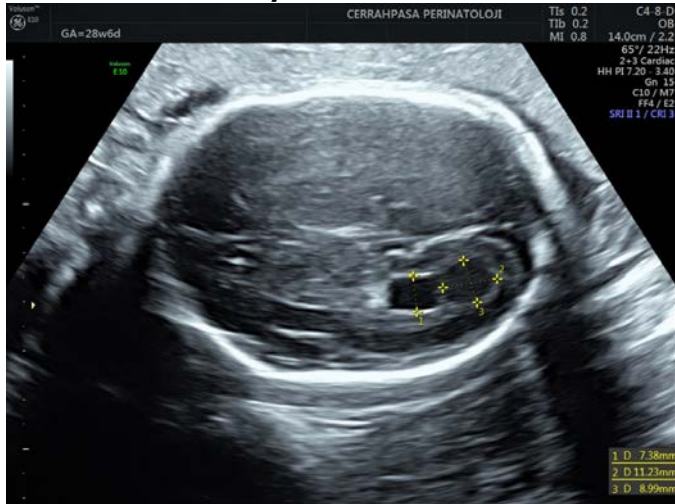Keywords: Fetal Intracranial Lesions, Intrauterine CMV Infection, Usage of Ultrasound in Pregnancy

Fetal Intracranial Cystic Lesions



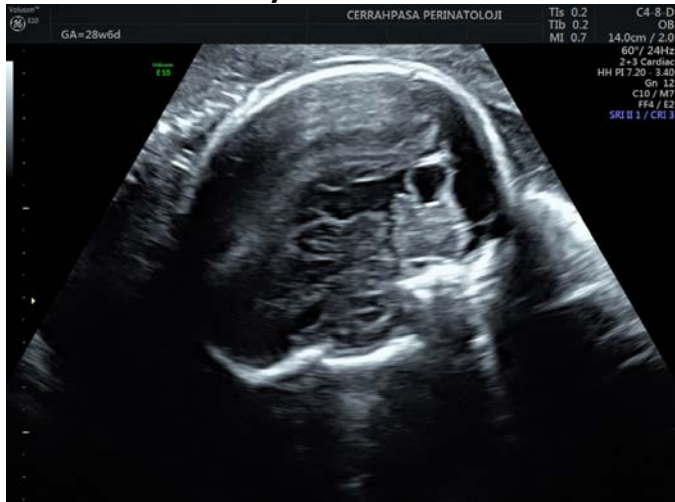Fetal Intracranial Cystic Lesions - Figure 3

Fetal Intracranial Cystic Lesions



Fetal Intracranial Cystic Lesions - Figure 2

Fetal Intracranial Cystic Lesions



Fetal Intracranial Cystic Lesions - Figure 1

PS-04

Presentation of an Operated Vulvar Cancer Patient with Leiomyosarcoma at the Operative Site

Ali Gökçe, Çağatayhan Öztürk, Gizem Çetinkaya Şendur, Salih Taşkın
Ankara University Medical School Department of Gynecology and Obstetrics

Introduction: With 16506 new cases, vulvar malignancies are the ninth most common cause of cancer in European women (1). It especially affects elderly women (1). Squamous cell carcinomas constitute the majority of cases. Age, incidence of human papillomavirus (HPV) infection, smoking, human immunodeficiency virus (HIV) infection, vulvar intraepithelial neoplasia and lichen sclerosus are the main epidemiological risk factors associated with vulvar cancer.

Postoperative radiotherapy should be offered to all patients with positive postoperative surgical margins where reexcision is not possible (2).

Method: A case of recurrent vulvar cancer which was followed up and treated in Ankara University Faculty of Medicine, Department of Obstetrics and Gynaecology, Division of Gynaecological Oncology is described.

Results: In 2019, a 60-year-old woman with a three-year history of vulvar itching had a biopsy of an ulcerated lesion adjacent to the urethra, which was reported as non-keratinized squamous cell carcinoma. Tumour diameter was 0.6*0.3 cm, depth of invasion was 0.2 cm; tumour continuity was present at the base surgical margin and lymphovascular area involvement was negative. Immunohistochemistry showed p16 negative, p53 patchy (wild type) positive, panCK positive, Ki67 full-fold positive staining. The patient was admitted to our clinic with the pathology result. On examination, a 3-4 cm mass extending to the lower 1/3 of the vagina on the right labium minus in the vulva was observed.

On imaging, computed tomography (CT) showed a 4*2 cm faintly limited contrast enhancing solid lesion in the right half of the vulva. Bilateral inguinal lymph nodes, the largest of which is 12*8 mm in size, are present. PET CT imaging showed no pathological involvement except for the lesion in the vulva.

In July 2019, right hemivulvectomy and bilateral inguinal lymph node dissection operation was performed. The pathology result was reported as moderately differentiated squamous cell carcinoma. Tumour long diameter was 5 cm, lymphovascular invasion was negative, deep surgical margin was 0.5 mm, depth of invasion was 6 mm; no invasive tumour continuity was

observed in the medial vaginal surgical margin, but HSIL (VAIN3) continuity was observed. Lateral anterior and posterior surgical margins were intact. Lymph node involvement was not observed (Stage 1b).

Adjuvantly, 50 Gy radiotherapy in conventional fractions is applied to the target including the entire vulva and lower 1/3 of the vagina.

In June 2023, the patient presented to our clinic with a 2.5 cm mass at the former operation site. There was no pathological involvement other than the lesion on PET examination at an external centre. Wide local excision is performed. Pathology revealed leiomyosarcoma; there was continuity in the deep surgical margin, no tumour continuity was observed in the lateral surgical margins. The patient will be discussed in the tumour council for follow-up and treatment plan and the decision will be made accordingly.

Conclusion: Radiotherapy after vulvar cancer surgery has been shown to increase survival and decrease recurrence rates. However, it should be kept in mind that cancers secondary to radiotherapy may be encountered in these patients.

Keywords: vulvar carcinoma, leiomyosarcoma, squamous cell carcinoma

PS-05

Prenatal diagnosis of fetal thymus hyperplasia by ultrasonography: Case report

Burak Bayraktar, Kadriye Yakut Yücel, Can Tekin İskender, Sevki Çelen

Department of Obstetrics and Gynecology, Division of Perinatology, Ankara Etlik City Hospital, Ankara, Turkey

BACKGROUND: Fetal thymus, situated in the mediastinum, is assessable through ultrasonography (US) and has been studied as a potential predictive factor in various pregnancy complications. While fetal thymus hypoplasia has garnered attention, fetal thymus hyperplasia remains a seldom-discussed anomaly. Here, we present a case of fetal thymus hyperplasia detected via prenatal US.

CASE: A 31-year-old, gravida 2, parity 1 woman with a history of one previous cesarean delivery presented at 38 weeks of gestation with labor pain. She had no significant medical history, and her living child was healthy. Initial US examination in the delivery room revealed fetal thymus hyperplasia within the 3-vessel trachea section (Figure 1). The patient subsequently underwent a cesarean section. Postnatally, the newborn underwent chest radiography and echocardiography,

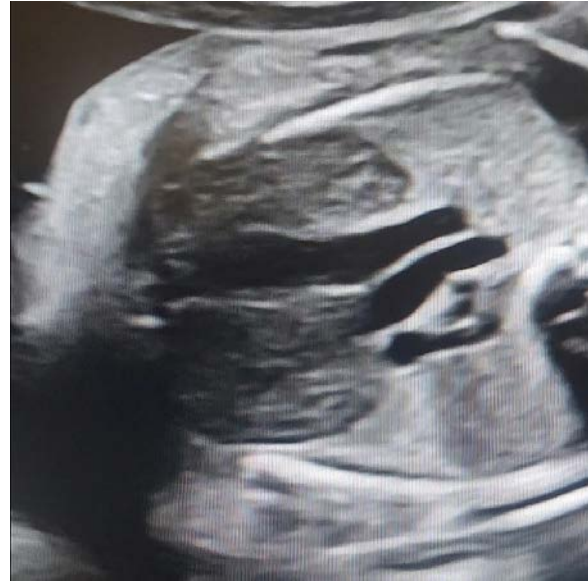which confirmed thymus hyperplasia. The newborn's blood tests, including hemogram, liver, and renal function, were within normal limits. Blood and urine cultures yielded negative results, and TORCH and parvovirus tests were also negative.

DISCUSSION: The thymus is an organ that develops from the endoderm mainly from the 3rd and 4th pharyngeal sacs during embryogenesis. It begins to develop at the 5th week of gestation, continues to grow until puberty, and then shrinks through atrophy. Fetal thymus hyperplasia is an exceedingly rare condition, and no prevalence data are available in the literature. In a previously reported case of a term fetus, no evidence of postnatal bacterial or viral infection was found, similar to our case. Our case was referred to an advanced fetal center for T lymphocyte count-ratio and magnetic resonance imaging (MRI).

CONCLUSION: Fetal thymus hyperplasia is an exceptionally rare prenatal finding. In cases like this, initial investigations should encompass routine blood tests, screening for bacterial and viral infections, T lymphocyte count-ratio analysis, and MRI to facilitate comprehensive evaluation and management. Further research is needed to better understand the implications and outcomes associated with fetal thymus hyperplasia.

Keywords: Fetal thymus, hyperplasia, prenatal diagnosis, fetal anomaly

Figure 1



Fetal thymus hyperplasia

ORGANİZASYON SEKRETARYASI



Figür Kongre Organizasyonları ve Tic. A.Ş.

19 Mayıs Mah. 19 Mayıs Cad. Nova Baran Center

No:4, 34360 Şişli / İstanbul

Tel: 0 212 381 46 00 - Faks: 0 212 258 60 78

E-posta: obstetrikjinekolojitartismalikonular@figur.net



www.obstetrikjinekolojitartismalikonular.org